

## Review

### THE SOMATOTOPY OF THE SPINAL CORD: A COMPREHENSIVE DESCRIPTION.

Lipari Alessio<sup>1</sup>, Romano Marcello<sup>2</sup>, Lipari Luana<sup>1</sup>, Farina Elvira<sup>1</sup>

#### Summary

For the benefit of medical students, in this paper we examine the somatotopic organization of the spinal cord, which shows a similar organization in mammals. The dorsal horn is comprised of sensory nuclei with deutoneurons; the lateral horn contains preganglionic visceral motoneurons; the ventral horn is subdivided into a medial column innervating the paravertebral muscles, a central column, C<sub>3</sub>-C<sub>6</sub>, innervating the diaphragm, and a lateral column innervating the limb muscles. In the lateral column of the ventral horn, the dorsal motoneuron groups innervate the intrinsic arm muscles; the dorsal posterior motoneuron groups innervate hand muscles; the lateroventral motoneuron groups innervate the shoulder. Furthermore, the rostral and caudal motoneuron groups innervate the proximal and the distal muscles, respectively. In cat spinal cord, the medial columns 1-2 innervate the paravertebral muscles, and columns 3-6 are divisible into groups, each innervating specific muscle groups. In human spinal cord, 11 motor columns have been identified: column 1 is located in the medial part and columns 2-11 in the lateral part of the ventral horn. Columns 1-2 extend to S<sub>3</sub>, while columns 3-8 are confined to the cervical and T<sub>1</sub> segments, and columns 9-11 are situated in the lumbosacral segments.

#### Introduction

The spinal cord lies in the vertebral canal and extends from the *foramen magnum* to the L<sub>1</sub>. It has a cervical and a lumbar enlargement, giving rise to the spinal nerves innervating the upper and the lower limbs, respectively.

The cross-sectioned spinal cord presents a central H-shaped area of *gray matter*, consisting of neurons and glial cell columns, surrounded by *white matter*, comprised of the ascending and descending myelinated fibers. Each half of the gray column extends throughout the length of the spinal cord, varying in configuration at different levels, and is subdivided into the *dorsal horn* that extends dorsolaterally, almost reaching the surface, the *ventral horn* that extends ventrally without reaching the surface, and the *lateral horn* located near the base of the ventral horn in the thoracic segments of the spinal cord. The ventral and dorsal gray commissures connect the gray matter of the two sides, encompassing the central canal. A white commissure, located ventral to the ventral gray commissure, is composed of transverse crossing fibers that arise from

#### Address of the authors:

1. Department of Experimental Biomedicine and Clinical Neurosciences. University of Palermo, Italy.
2. Department of Neurology, Hospital "Cervello-Villa Sofia", Palermo, Italy.

Send correspondence to: : Alessio Lipari, [alessio.lipari@tiscali.it](mailto:alessio.lipari@tiscali.it)

Received: 21th April, 2016 — Revised: 29th April, 2016 — Accepted: 01st May, 2016

nerve cells in the gray matter, and extends to the anterior median fissure. The gray matter is subdivided in Rexed laminae I-X [1].

Although countless studies have been conducted on various aspects of the spinal cord, with this study, we wanted to highlight the somatotopic architecture of the gray substance, focusing on both sensory information and origin of muscle groups. Below, we describe the somatotopic architecture of the spinal cord gray matter, which is divided into ventral, dorsal and lateral horns.

### Ventral horn

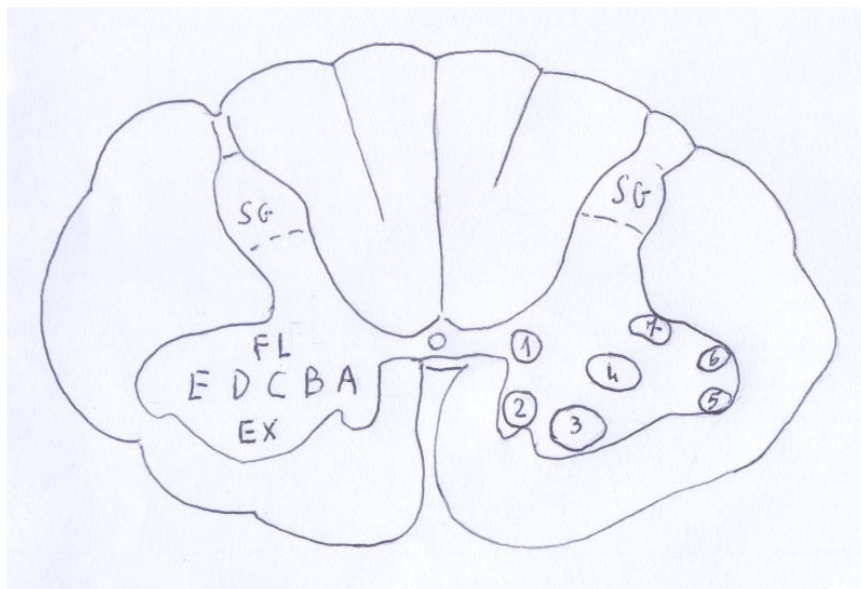
The ventral horn [2, 3] of the gray matter presents lengthened motoneuron groups, extending over several spinal cord segments, and is arranged into three columns (Figure 1). The projection of motoneuron axons to specific muscles and their action are correlated with their anatomical position. Medially located neuronal pools innervate the axial and proximal muscles, while laterally located neuronal pools innervate the distal muscles; furthermore, ventrally located neu-

ron pools within the ventral horn innervate the extensor muscles, whereas the more dorsal neuron pools innervate the flexor muscles. The axons of descending motor pathways are classified according to their termination in the medial and lateral spinal cord.

The *ventral horn* is subdivided into three columns: medial, central, and lateral.

The *medial column* extends for the entire length of the spinal cord in the rostrocaudal axis (it can be absent in L<sub>5</sub> and S<sub>1</sub>), and is further subdivided into ventromedial and dorsomedial columns in the thoracic and first lumbar segments. In the other segments, only the ventromedial component is present, while in C<sub>1</sub>, only the dorsomedial column is present.

The medial motor column innervates, through the dorsal ramus of the spinal nerve, the epiaxial paravertebral muscles (erector spinae muscles; head and spine extensor muscles) and, through the ventral ramus of the spinal nerve, the hypoaaxial muscles (prevertebral neck muscles, intercostal muscles, muscles of the anterior abdominal wall; neck and trunk flexor muscles). Thus, the motoneurons



**Figure 1.** Transverse section at cervical level of the spinal cord. 1-7: positions of the motoneuron groups. 1. Posteromedial; 2. Anteromedial; 3. Anterior; 4. Central; 5. Anterolateral; 6. Posterolateral; 7. Retroposterolateral. A-E: Medial-lateral direction of the neuronal groups in relation to the innervated muscles. A. Trunk; B. Shoulder; C. Arm, D. Forearm; E. Hand. The flexor muscles (FL) are in a dorsal position, the extensor muscles (EX) are in a ventral position, (SG) substantia gelatinosa.

Figure modified from: Carpenter MB: Human Neuroanatomy, seventh edition. The Williams & Wilkins Company. Baltimore 1976.

of the epiaxial (extensor) muscles are ventrally located, while those for the hypoaxial (flexor) muscles are situated dorsally.

In the *central column*, the phrenic nucleus is located between segments C<sub>3</sub>-C<sub>7</sub>. Another neuron group, situated between segments C<sub>1</sub>-C<sub>6</sub>, in the ventral border of the ventral horn, gives rise to the axons of the spinal accessory nerve.

The *lateral column* is present in the cervical and lumbar enlargements only, and consists of the neurons innervating the muscles of the upper and lower limbs, respectively.

The *lateral column* is further subdivided into three subgroups: ventral, dorsal, and dorsal posterior. The dorsal motoneuron groups innervate the intrinsic muscles of the arm, while the dorsal posterior motoneuron groups innervate the distal muscles (hand), and the lateroventral motoneuron groups innervate the shoulder.

Furthermore, the rostral motoneuron groups innervate the proximal muscles and the caudal motoneuron groups innervate the distal muscles.

Motoneurons located in segments C<sub>5</sub>-C<sub>6</sub> innervate the shoulder muscles, while those located in C<sub>8</sub>-T<sub>1</sub> innervate the intrinsic hand muscles, and L<sub>1</sub>-L<sub>2</sub> and S<sub>3</sub> neuron groups innervate the hip muscles and the intrinsic muscles of the foot, respectively.

In S<sub>1</sub>-S<sub>2</sub>, a ventrolateral group of neurons, probably Onuf's nucleus, innervates the striated muscles of the perineum.

Some important studies regarding the somatotopy of motoneuron groups supplying the limb muscles have been previously published.

Tada and colleagues [4] studied the topographical localization of rat spinal motoneurons supplying the forelimb during development, and found that:

- the motoneurons supplying the *biceps brachii muscle* are located in the dorsolateral nucleus of the anterior horn of the 4<sup>th</sup> cervical segment and extend downward to the ventral nucleus in 8<sup>th</sup> cervical segment, forming a spindle-shaped cell column;
- the motoneurons supplying the *triceps brachii muscle* are located in the

ventromedial nucleus of the anterior horn of the 6<sup>th</sup>, 7<sup>th</sup> and 8<sup>th</sup> cervical segments, forming a spindle-shaped cell column;

- the motoneurons supplying the *flexor carpi ulnaris muscle* are located in the 7<sup>th</sup> and 8<sup>th</sup> cervical segment, and were fewer in number compared to those supplying the biceps and triceps brachii muscles.

These authors also found that a drastic decrease in motoneurons occurs over the course of the first 50 weeks, when the number of motoneurons corresponds to about 13% of those in two week old rats. Moreover, in immature rats (10 days-2 weeks of age) the muscles are bilaterally innervated by the spinal nerve; this bilateral motor innervation was found to disappear with maturation.

Romanes [5] identified *6 columns* in cat spinal cord in the L<sub>4</sub>-S<sub>2</sub> tract.

Columns 1-2 give rise to motor fibers in the *dorsal* division of the ventral primary rami, which can be divided into two main groups.

Column 1 gives rise to fibers innervating muscles acting on the hip and the knee. In column 2, the cranial part (ventrally located) gives rise to fibers innervating knee muscles, while the caudal part (dorsally located) gives rise to fibers innervating ankle and toe muscles.

Columns 3-6 give rise to motor fibers in the *ventral* division of the ventral primary rami, divisible into a series of groups, each innervating specific muscle groups, as follows:

column 3 gives rise to fibers innervating the hip and the gracilis muscles; columns 3'- 3'' give rise to fibers innervating hip and knee muscles;

column 4 gives rise to fibers innervating ankle and toe muscles;

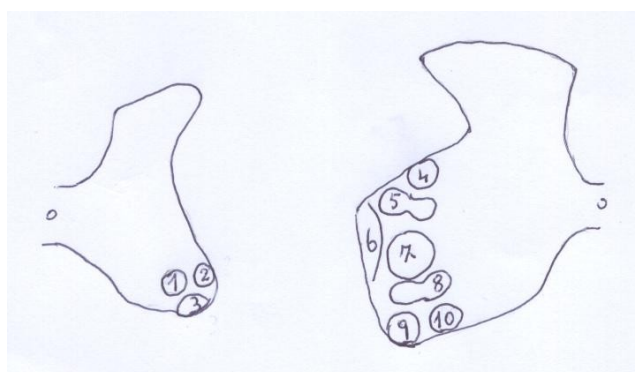
column 5 gives rise to fibers innervating knee and ankle muscles, and the popliteus muscle;

column 6 gives rise to fibers innervating toe muscles.

Romanes [5] studied the topography of neurons innervating the muscles of the lower limb in cat, and identified several neuron groups (Figure 2) organized in the rostrocaudal direction (L<sub>4</sub>-S<sub>2</sub>). The data are summarized in Table 1.

Apical segments	Anteriorly	Posterolaterally	Posteromedially
L4-L5	Sartorius; Rectus femoris		
L5-L6		Vastus lateralis/ medialis	Gracilis
L6-L7		Peroneus longus; Secundus/tertius Per- oneus Tibialis anterior	Semimembranosus
L6-S1		Peroneus longus	
L7			
Caudal segments	Anteriorly	Medially	Laterally
L5-L6	Adductor magnus		
L5-L6			Vastus medialis/ lateralis
L6-L7		Gastrocnemius later- alis Tibialis posterior	Extensor digitorum brevis/longus Gluteal superior; Tibialis anterior
L7		Popliteus Soleus	
L6-S1	Quadriceps femoris		Gluteal inferior; Peroneus longus
L7-S1	Biceps; semitendinosus	Gastrocnemius medialis	
	Flexor digitorum longus. Flexor hallucis longus		

**Table 1.** Origin and innervations of the hindlimb muscles; from Romanes [5].



**Figure 2.** Transverse sections at mid L<sub>4</sub> (left) and base of S<sub>2</sub> (right). 1. Gracilis. Semimembranosus; 2. Vastus lateralis/medialis. Extensor digitorum brevis/longus. Tibialis anterior. Peroneus longus; 3. Rectus femoris. Sartorius; 4. Medial /lateral plantar; 5. Flexor hallucis longus. Flexor digitorum longus; 6. Extensor digitorum brevis. Peroneus secundus/tertius. Extensor digitorum longus. Tibialis anterior. Peroneus longus. Vastus lateralis/medialis; 7. Medial/lateral gastrocnemius. Soleus. Tibialis posterior. Popliteus; 8. Biceps. Semitendinosus; 9. Superior/inferior gluteal; 10. Obturator internus. Quadratus femoris.

Figure modified from: Romanes G.: J Comp Neurol 1951; XCIV: 339

McHanwell and Biscoe [6] studied the location of the motoneurons supplying mouse hindlimb muscles (Figure 3) and reported that:

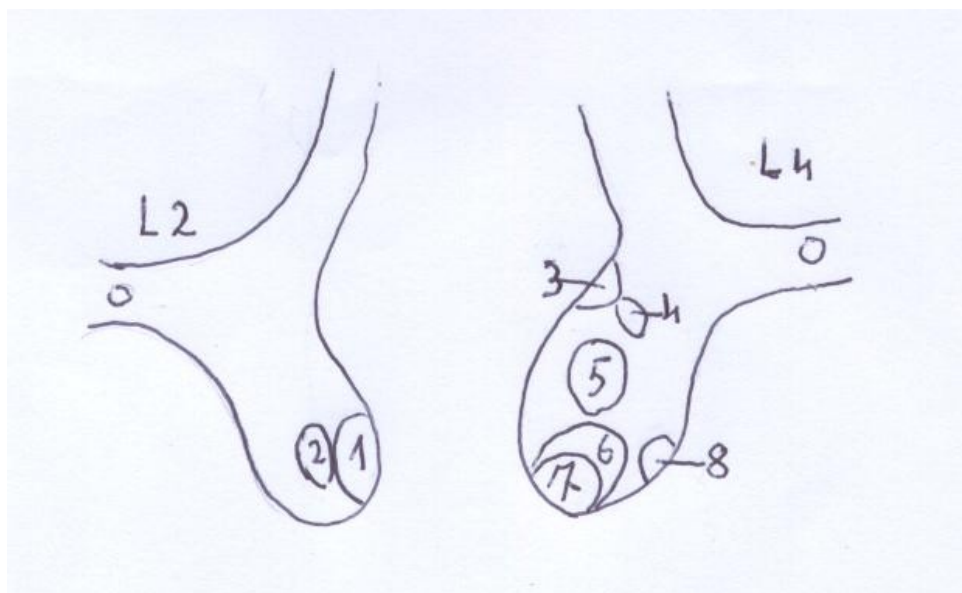
- The nucleus of the quadriceps muscle originates from the upper third-base of L<sub>1</sub>, and terminates in the upper half of L<sub>3</sub>.
- The sartorius muscle is observable only from the 13<sup>th</sup> day of fetal life.
- The adductor and gracilis muscles' nuclei are located in L<sub>2</sub>, some in L<sub>3</sub>. The adductor nucleus starts in the upper half of L<sub>1</sub> and terminates at the base of L<sub>2</sub> or upper half of L<sub>3</sub>, and occupies a more ventral and medial position, contiguous with the medial border of the nucleus of the quadriceps muscle. The nucleus of the gracilis muscle is located in lower L<sub>2</sub> and upper L<sub>3</sub>. The nuclei of the gracilis and adductor muscles overlap, except in the caudal region of the gracilis nucleus, which is situated dorsally to the adductor muscles.
- The pectineus muscle nucleus extends from the lower half of L<sub>1</sub> to the upper L<sub>2</sub>, and maintains a lateral and ventral position throughout its length.

- The nucleus of the gluteal muscle is located caudally respect to the nuclei of the muscles described above; its motoneuron groups are located in L<sub>3</sub>-L<sub>4</sub>, starting in the upper quarter of L<sub>3</sub> and terminating in the lower quarter of L<sub>4</sub>. Its upper region is located at a ventrolateral position medially, and dorsally it is positioned in L<sub>3</sub>-L<sub>4</sub>.

The data are summarized in Table 2.

Recently, Sengul and colleagues [7] studied the cytoarchitecture in postnatal mouse spinal cord, based on the laminar scheme described by Rexed in the cat spinal cord [8, 9]. Furthermore, these authors reported the morphology and position of different neuron groupings in postnatal mouse (P4), which was essentially identical to that found in adult mouse spinal cord. The data are summarized in Table 3.

Somatotopically, in both the upper and the lower limbs, the motoneurons innervating proximal muscles are located rostrally, while the motoneurons innervating distal muscles are located caudally. Thus, the muscles of the hand are located in C<sub>8</sub>-T<sub>1</sub>, and the muscles of the shoulder are located in C<sub>5</sub>.



**Figure 3.** Transverse sections at mid L2 (left) and base of L4 (right). 1. Quadriceps femoris; 2 Adductors (Gracilis-Pectineus); 3. Anterior/lateral crus muscles (superficial and deep peroneal); 4. Foot (medial/lateral plantar); 5. Posterior crus muscles (triceps surae - deep posterior muscles); 6. Hamstring (semitendinosus, biceps, semimembranosus, caudofemoralis, quadratus femoris); 7. Gluteal muscles; 8. Inner pelvic. Figure modified from: McHanwell and Biscoe. *Philos Trans R Soc Lond B Biol Sci.* 1981; 293: 498.



### 1.1 Upper limb muscles

The neurons innervating the upper limb muscles are organized in the craniocaudal direction [10]. The data are summarized in Table 4.

### 1.2 Lower limb muscles

Gray [2] reported that the neurons innervating the lower limb muscles are located in the craniocaudal direction, in the sequence summarized in Table 5.

Lundy-Elkman [10] reported that the neurons innervating the lower limb muscles are located in the craniocaudal direction, in the sequence summarized in Table 6.

Recently, Ba'cskai and colleagues [11] confirmed the data from previous studies [12, 13], reporting that in mouse spinal cord, the arrangement of the individual motoneuron groups is related to the on-

togenetic origin, localization and function of the innervated muscles.

Three longitudinal motoneuron columns were identified:

- *dorsolateral column*, which extends from L<sub>4</sub> to L<sub>6</sub>, and consists of motoneurons innervating the crural and foot muscles;
- *ventrolateral column*, which extends from L<sub>1</sub> to L<sub>6</sub>, and accommodates motoneurons supplying the iliopsoas, gluteal, and quadriceps femoris muscles;
- *central column*, which is located in the middle part of the ventral horn between L<sub>2</sub> and L<sub>6</sub>, and consists of motoneurons for the thigh adductor, hamstring, and quadratus femoris muscles.

Within these longitudinal columns, the arrangement of the different motoneuron groups reflects their somatotopic organization. In the ventral column, the moto-

Segments	Muscles
L1-L2	Pectineus
L1-L3	Quadriceps
L2-L3	Adductors Gracilis
L3-L4	Gluteal muscle Hamstring

**Table 2.** Origin and innervations of the hindlimb muscles; from McHanwell and Biscoe [6].

Neural segments	Muscles
C3-C5	phrenic
C4-C6	deltoid and biceps
C5-C6	infraspinatus and supraspinatus
C7-T1	pectoralis M. triceps groups
L1	Cremaster
L2-L3	Quadriceps
L2-L3	Thigh adductor
L3-L6	M crural flexor
L4-L6	Hamstring
L6	Foot dorsolaterally

**Table 3.** Origin and innervation of muscles; from Sengul [7].

Neural segments	Muscles
C <sub>2</sub> -C <sub>3</sub>	Sternocleidomastoideus. Trapezium
C <sub>3</sub> -C <sub>5</sub>	Levator scapulae. Phrenic
C <sub>4</sub> -C <sub>5</sub>	Rhomboid
C <sub>4</sub> -C <sub>6</sub>	Supraspinatus
C <sub>5</sub> -C <sub>8</sub>	Serratus anterior
C <sub>5</sub> -C <sub>6</sub>	Biceps. Brachialis. Deltoid
C <sub>5</sub> -C <sub>7</sub>	Pectoralis, its major head clavicular. Supinator
C <sub>6</sub> -C <sub>7</sub>	Pronator teres
C <sub>6</sub> -C <sub>8</sub>	Latissimus dorsi. Triceps Long extensor of wrist and fingers
C <sub>6</sub> -T <sub>1</sub>	Pectoralis, its major sternal head
C <sub>7</sub> -T <sub>1</sub>	Long flexor of the wrist and fingers
C <sub>8</sub> -T <sub>1</sub>	Hand intrinsic

**Table 4.** Origin and innervations of upper limb muscles; from Lundy-Ekmann [10].

Neural segments	Muscles
L <sub>1</sub> -L <sub>3</sub>	Iliopsoas. Sartorius
L <sub>2</sub> -L <sub>3</sub>	Pectineus. Gracilis
L <sub>2</sub> -L <sub>4</sub>	Abductor longus/brevis./magnus. Quadriceps
L <sub>2</sub> -L <sub>3</sub>	Obturatorius externus
L <sub>4</sub> -L <sub>5</sub>	Tibialis anterior/posterior
L <sub>4</sub> -S <sub>1</sub>	Tensor fasciae latae. Gluteus parvus/medius. Semitendinosus.
L <sub>5</sub> -S <sub>1</sub>	Gastrocnemius. Extensor longus hallucis. Extensor digitorum longus. Peroneus tertius
L <sub>5</sub> -S <sub>2</sub>	Peroneus brevis/longus. Piriform. Obturator internus/ externus. Gemellus superior//inferior. Quadratus femoris. Plantaris. Biceps. Gluteus maximus
S1-S2	Flexor longus /brevis hallucis
S1-S3	Flexor digitorum longus/brevis
S2-S3	Intrinsic muscles pedis

**Table 5.** Origin and innervations of lower limb muscles; from Gray [2].

neurons innervating muscles developing from the dorsal mass (e.g. quadriceps) are situated in the lateral part of the column, while the motoneurons innervating muscles developing from the ventral muscle mass (e.g. hamstring) are situated in the medial part of the column. Motoneuron pools belonging to proximal muscles (e.g. quadratus femoris and iliopsoas) are situated ventrally to those supplying the more distal muscles (e.g. plantar muscles). Finally, motoneurons innervating the flexor muscles (e.g. dorsal crural muscles) are located more medially than those supplying the extensor muscles of the same joint (e.g. anterior crural muscles) (Table 7).

Another article [14] reported the findings of a study on the motoneuron groups and columns in the ventral horn of human spinal cord. In the cervical region, neuronal groups were more numerous,

but smaller and less distinct, while in the lumbosacral region they were fewer, larger and at many levels better circumscribed. 11 motor columns were identified (Table 8):

- column 1 was located in the medial division of the ventral gray horn;
- columns 2-11 was located in the lateral division of the ventral gray horn;
- columns 1 and 2 were the most extensive, as they were traceable from the lower medulla to S<sub>3</sub>;
- columns 3-8 were confined to the cervical segments (including T<sub>1</sub>);
- columns 9-11 were traced in lumbosacral segments.

In general, motor columns were found to follow a definite mode for their appearance and disappearance. Many of them displayed a rotation from a dorsal to a ventromedial direction.

Neural segments	Muscles
L <sub>2</sub> -L <sub>4</sub>	Iliopsoas. Adductors
L <sub>3</sub> -L <sub>4</sub>	Quadriceps. Obturatorius externus
L <sub>4</sub> -L <sub>5</sub>	Tibialis anterior/posterior
L <sub>4</sub> -S <sub>1</sub>	Tensor fasciae latae. Gluteus parvus/medius.
L <sub>5</sub> -S <sub>1</sub>	Hamstrings. Extensor hallucis longus. Extensor digitorum longus. Peroneus longus /brevis
L <sub>5</sub> -S <sub>2</sub>	Gluteus maximus
S <sub>1</sub> -S <sub>2</sub>	Triceps
S <sub>2</sub> -S <sub>3</sub>	Intrinsic muscles pedis

**Table 6.** Origin and innervations of the lower limb muscles; from Lundy- Ekmann [10].

Column	Neural segments	Muscles in latero-medial direction
Dorsolateral	L <sub>4</sub> - L <sub>6</sub>	Lateral crural. Anterior crural. Extensor digitorum brevis. Plantar.
Ventrolateral	L <sub>1</sub> - L <sub>6</sub>	Iliopsoas. Gluteal superficialis. Gluteus medius. Quadriceps femoris.
Central	L <sub>2</sub> - L <sub>6</sub>	Semitendinosus. Semimembranosus. Biceps femoris anterior. Biceps femoris posterior. Pectineus. Adductor longus. Adductor magnus. Gracilis. Quadratus femoris.

**Table 7.** Origin and innervations of the lower limb; from Ba' cskai et al. [11].



Neural segments	Medial column		Lateral column										
	1	2	1	2	3	5	4	6	7	8	9	10	11
C <sub>1</sub>	+	+	+	+									
C <sub>2</sub>	+	+	+	+	+								
C <sub>3</sub>	+	+	+	+	+		+						
C <sub>4</sub>	+	+	+	+	+	+	+						
C <sub>5</sub>	+	+	+	+	+	+	+						
C <sub>6</sub>	+	+		+	+	+	+						
C <sub>7</sub>	+	+		+	+	+	+	+					
C <sub>8</sub>	+	+	+					+	+	+			
T <sub>1</sub>	+	+	+					+	+	+			
T <sub>2</sub>	+		+										
T <sub>3</sub>	+		+										
T <sub>4</sub>	+		+										
T <sub>5</sub>	+		+										
T <sub>6</sub>	+		+										
T <sub>7</sub>	+		+										
T <sub>8</sub>	+		+										
T <sub>9</sub>	+		+										
T <sub>10</sub>	+		+										
T <sub>11</sub>	+		+										
T <sub>12</sub>	+		+										
L <sub>1</sub>	+		+										
L <sub>2</sub>	+		+								+		
L <sub>3</sub>	+		+								+		
L <sub>4</sub>	+		+								+	+	
L <sub>5</sub>			+								+	+	
S <sub>1</sub>			+								+	+	+
S <sub>2</sub>	+		+								+	+	+
S <sub>3</sub>	+		+									+	+
S <sub>4</sub>	+												
S <sub>5</sub>													
CO <sub>1</sub>													

**Table 8.** Columns and motoneuron groups in the ventral horn of the human spinal cord; from Roulal and Pala. [14].

### Dorsal horn

The dorsal horn [15] of the gray matter is divided into head, neck and base. Studies have revealed a cytoarchitectonic organization with nine distinct cellular laminae, Rexed laminae I-IX, and Rexed lamina X [1] which is the gray commissure surrounding the central gray matter present in all segments of the spinal cord.

The dorsal horn, in the posteroanterior direction, is subdivided into:

*nucleus posteromarginalis* (Nucleus magnocellularis pericornualis, marginal cells; Rexed lamina I) that is a thin layer of cells covering the tip of the dorsal horn; *substantia gelatinosa* (Rexed lamina II) is located beneath the marginal cells, extending the whole length of the cord, and is largest in the lumbosacral and first cervical segments. This nucleus constitutes the primary associative center of the dorsal horn for incoming impulses;

*nucleus proprius* (nucleus centrodorsalis, nucleus magnocellular centralis; Rexed laminae III-IV) occupies the head and neck of the dorsal horn medially. This nucleus processes proprioceptive and two-point discrimination information;

*reticular nucleus* (Rexed lamina V) is located lateral to the *nucleus proprius*. This nucleus consists of cells found in the reticular process;

*nucleus dorsalis* (nucleus thoracicus, column of Clarke, nucleus magnocellular basalis, nucleus spinocerebellaris; Rexed lamina VII) is a striking cell column in the medial section of the base of the dorsal horn. It extends from C8 to T10 upper lumbar segments, being most prominent in T10, T12 and L1. This nucleus receives fibers of the proprioceptors and gives rise to the uncrossed posterior spinocerebellar tract.

At the cervical levels C<sub>5</sub>-C<sub>7</sub>, the separate, elongated columns in the middle layers of the dorsal horn of the macaque monkey spinal cord [16] receive the afferent fibers from digits 1-5, terminated in a rostrocaudal sequence. Afferent fibers from the glabrous digits extend to the medial margin of the dorsal gray, while afferent fibers from the dorsal skin of the digits terminate more laterally. Afferent fibers from the dorsal hand and palm ter-

minate lateral to those from the digits, while inputs from the forearm occupy tissue rostral and caudal to the representation of the hand.

The *intermediolateral nucleus* consists of several adjacent cell columns. The most lateral apical cell group constitutes the lateral horn (Rexed lamina VII) with preganglionic ortosympathetic neurons in C<sub>8</sub>/T<sub>1</sub>-L<sub>2</sub> and parasympathetic preganglionic neurons in S<sub>2</sub>-S<sub>4</sub>.

### Lateral horn

The lateral dorsal horn [10] contains the cell bodies of preganglionic sympathetic neurons. It is present only at spinal segments T1-L2. A region analogous to the lateral horn, located in the S<sub>2</sub>-S<sub>4</sub> segments, includes the preganglionic parasympathetic cell bodies. Preganglionic autonomic neurons are efferent neurons. Both the sympathetic and parasympathetic preganglionic neurons exit the cord via the ventral root.

*Intermediolateral nucleus* extends between C<sub>8</sub>/T<sub>1</sub>-L<sub>2</sub> and consists of the visceral efferent neurons; the most lateral apical cell group constitutes the lateral horn (Rexed lamina VII) with preganglionic ortosympathetic neurons in C<sub>8</sub>/T<sub>1</sub>-L<sub>2</sub> and parasympathetic preganglionic neurons in S<sub>2</sub>-S<sub>4</sub>.

*Intermediolateral nucleus*, situated in the intermediate gray, consists of a rather diffusely organized cell group.

*Dorsal and ventral commissural nuclei* are two less definite columns extending the length of the spinal cord. They form intersegmental tracts in the dorsal and ventral white funiculi, respectively.

*Sacral autonomic nuclei* are groups of neurons located along the lateral surface of the base of the ventral gray horn in sacral segments S<sub>2</sub>-S<sub>4</sub>; their axons leave the spinal cord via the ventral root of the spinal nerve as preganglionic (sacral) parasympathetic fibers.

Recently, Sengul and colleagues [7] studied the somatotopy in P4 mouse spinal cord, which is similar to that of the adult mouse, as described below.

The *dorsal nucleus* or Clarke's column extends from T<sub>1</sub> to L<sub>3</sub> and occupies the medial part of Rexed lamina V of the spinal gray.

The *internal basilar nucleus* is located in the ventromedial dorsal horn, within the limits of Rexed lamina IV, in segments C<sub>1</sub>–C<sub>6</sub>.

The *central cervical nucleus* is located in Rexed lamina V, just lateral to the upper part of lamina X at segmental levels C<sub>1</sub>–C<sub>5</sub>, and is composed of large multipolar neurons with dendrites radiating dorso-laterally, laterally and ventrally, and, occasionally, of small triangular and spindle-shaped neurons.

The preganglionic cell columns of the sympathetic system are found in Rexed lamina VII. These include the intermediolateral nucleus and the intercalated nucleus.

The *intermediolateral nucleus* is located at the lateral edge of Rexed lamina VII, and forms the “intermediolateral horn” in segments T<sub>1</sub>–L<sub>1</sub> in ICI<sub>Pe</sub> (paraependymal part of the intercalated nucleus). In Rexed lamina VII of segments T<sub>2</sub>–L<sub>1</sub>, the intercalated nucleus (ICI) forms a series of bridges connecting the intermediolateral column (IML) with the central autonomic area (ICI<sub>Pe</sub>) in lamina X, dorsolateral to the central canal.

*Sacral parasympathetic nucleus* consists of parasympathetic preganglionic neurons that innervate the pelvic visceral organs and receives projections from pelvic visceral afferents. It is located in the dorsolateral part of Rexed lamina VII in segments S<sub>1</sub>–S<sub>2</sub>.

The *intermediomedial column* (IMM) consists of small to medium-sized triangular neurons. The IMM is located immediately lateral to and partly embedded in Rexed lamina X, along laminae IV–V borders in C<sub>1</sub>–C<sub>5</sub>, in laminae V–VI in C<sub>6</sub>–C<sub>8</sub>, and in lamina VII in segments T<sub>1</sub>–L<sub>2</sub>.

The *lumbar dorsal commissural nucleus* consists of round, oval-, or spindle-shaped neurons located along the midline of lamina VII in T<sub>11</sub>–L<sub>1</sub>, in the dorsal gray commissure.

The *sacral dorsal commissural nucleus* is located in the medial part of lamina V in L<sub>6</sub>. Caudally, in S<sub>1</sub>–S<sub>4</sub>, it occupies the medial parts of Rexed laminae II and III–V, and a relatively small area dorsal to lamina X in L<sub>6</sub> and S<sub>1</sub> segments, and becomes larger in S<sub>2</sub>–S<sub>3</sub>.

The *sacral precerebellar nucleus* (SPrCb)

is located in Rexed lamina VII of segments S<sub>1</sub>–S<sub>4</sub>, and consists of large multipolar neurons. In L<sub>1</sub>–L<sub>3</sub>, a lumbar precerebellar nucleus can also be identified in Rexed lamina VII, presumably similar to SPrCb in structure and function.

### Conclusions

From the data reported, it is evidenced that the spinal cord displays a somatotopic organization, similar in different mammals. The arrangement of the individual motoneuron groups is related to the ontogenetic origin, localization and function of the muscles they supply. In the ventral horn, the rostral and caudal motoneuron groups innervate the proximal and distal muscles, respectively. Furthermore, the motoneuron groups are located in a mediolateral sequence from the medial paravertebral muscles to proximal-distal limb muscles, as well as in a dorsoventral sequence, with the flexor muscles located dorsally and the extensor muscles located ventrally.

The knowledge of the somatotopy of the motoneuron groups innervating specific muscles is vital to accurately establish the correlation between peripheral muscle lesions and the corresponding central neuronal loci within the spinal cord.

### References

1. Rexed B: Some aspects of the cytoarchitecture and synaptology of the spinal cord. In: Progress in Brain Research. Organization of the spinal cord. J.C. Eccles and J.P. Schade (Editors) Elsevier Publishing Company. Amsterdam. Vol. 11:58-92; 1964..
2. Gray's Anatomy. The Anatomical Basis of Clinical Practice, edited by Standring Susan. 40<sup>th</sup> ed. Elsevier. 2008.
3. Carpenter MB: Human Neuroanatomy, seventh edition. The Williams & Wilkins Company. Baltimore 1976.
4. Tada K, Yonenobu K, Ohshita S, Ono K: The topographical localization of spinal motoneurons of the rat and its numerical alternation in regard to development (author's transl). Nihon Seikeigeka Gakkai Zasshi. 1979; 53:807-16.

5. Romanes GJ: The motor cell columns of the lumbo-sacral spinal cord of the cat. *J Comp Neurol* 1951; 94:313-363.
6. McHanwell S. and Biscoe TJ: The localization of motoneurons supplying the hindlimb muscles of the mouse. *Philos Trans R Soc Lond B Biol Sci.* 1981; 293:477-508.
7. Sengul G, Puchalski RB, Watson C: Cytoarchitecture of the spinal cord of the postnatal (P4) mouse. *Anat Rec.*2012;
8. Rexed B: The cytoarchitectonic organization of the spinal cord in the cat: *J Comp Neurol* 1952; 96:415-95.
9. Rexed B: A cytoarchitectonic atlas of the spinal cord in the cat: *J Comp Neurol* 1954; 100:297-379.
10. Lundy-Ekman L: *Neuroscience. Fundamental for Rehabilitation.* 4<sup>th</sup> Edition. Saunders Elsevier, 2007.
11. Ba'cskai T, Ruzsna'k Z, Paxinos G, Watson C: Musculotopic organization of the motor neurons supplying the mouse hindlimb muscles: a quantitative study using Fluoro-Gold retrograde tracing. *Brain Struct Funct* 2014; 219:303-321. DOI 10.1007/s00429-012-0501-7 318
12. Lance JC: The morphogenesis of the thigh of the mouse with special reference to tetrapod muscle homologies. *J Morphol* 1979; 162:275-310
13. Ryan JM, Cushman J, Jordan B, Samuels A, Frazer H, Baier C: Topographic position of forelimb motoneuron pools is conserved in vertebrate evolution. *Brain Behav Evol* 1998; 51:90-99.
14. Routal RV and Pala GP: A study of motoneuron groups and motor columns of the human spinal cord. *J Anat* 1999; 195:211-224
15. Delmas A: *Vie e centri nervosi. Introduzione alla Neurologia.* II ed. italiana. UTET, 1977.
16. Florence SL, Wall JT, Kaas JH: Somatotopic organization of inputs from the hand to the spinal gray and cuneate nucleus of monkeys with observations on the cuneate nucleus of humans. *J Comp Neurol* 1989; 286:48-70.