

EXPERIENCES THAT “REACH THE HEART”. TAKING PART IN A WHOLE BODY DISSECTION COURSE AT THE UNIVERSITY OF MALTA

Pietro Pollara ^{1*}, Martina Inzerauto ^{1*}, Noemi Ravi ^{1*}, Claudio Tomasino ^{1*}, Alberto Scorsoni ^{1*}, Beatrice Liguoro ^{1*}, Francesco P. Busardò ^{1*}, Feres Slama ^{1*}, Rossella Capitemmino ^{1*}, Enrico Seidita ^{1*}, Giovanni Tomasello ^{2^}, Francesco Carini ^{2^}, Cristoforo Pomara ³.

1. School of Medicine and Surgery, University of Palermo, Italy;
2. Department of Experimental Biomedicine and Clinical Neuroscience, University of Palermo, Italy.
3. Department of Anatomy, School of Medicine, University of Malta, Msida, Malta.

*These authors were the medical students at the University of Palermo that performed the experience at the University of Malta, and they contributed equally to this work.

^ These authors are Faculty at the University of Palermo and guided the students to write the text of this paper.

ARTICLE INFO

Article history:

Received 15 June 2017

Revised 21 July 2017

Accepted 09 August 2017

Keywords:

Whole Body Dissection Course, heart dissection, coronary arteries.

ABSTRACT

This article summarizes the activities of the four-week whole body dissection course the main authors participated in in August 2016 at the dissection hall of the University of Malta (UoM). Our team comprised 10 second-year medicine students from University of Palermo chosen among who had passed the Human Anatomy exam brilliantly. The need to move to the UoM to take part in such activity derives from the lack of practice approach in Italian schools of medicine, focused mostly on the theoretical studies, neglecting practical experience. The heart dissection reveal itself as a huge opportunity to finally apply our anatomical knowledge, improving it and enabling us to compare images took from books to the actual organ. We had the chance to handle a real heart, to appreciate its weight and consistence. We took part in coronary artery courses focusing on their functions within the heart machinery.

© EuroMediterranean Biomedical Journal 2017

1. Introduction

A good medical training means tying up study and practice, head and hands, knowledge and experience (1 - 3). According to this idea, we were selected, because of our brilliant career in the University of Palermo (UoP), to take part in an accomplishment of four week course of whole cadaveric dissection and completion of regional anatomical projects at the University of Malta (UoM). This stage revealed us how it's very hard to project the images of the book into a real human body with all sophisticated and strong relations.

The course took place in University Dissection hall, where we spent our time to cut and separate the body structures with the supervision and guidance of Professor Pomara. He showed and taught us the dissection

techniques to be more independent and to figure on our own the beauty of science and we can demonstrate our interesting experience thanks to EuroMediterranean Biomedical Journal (for young doctors) (4, 5). Each of us had a personal surgical kit and we started from the dissection of the cutis and subcutis to familiarize with our instruments.

In this article we focus on heart anatomy, following the coronary arteries in all its complexity and charm.

2. Material and methods

The dissection of the human heart allowed us to develop a comprehensive understanding and a strong basis for a long-term retention of its anatomy (6-8). The UoM provided an adult male cadaver that was used for the

* Corresponding author: Giovanni Tomasello, giovanni.tomasello@unipa.it

DOI: 10.3269/1970-5492.2017.12.22

All rights reserved. ISSN: 2279-7165 - Available on-line at www.embj.org

dissection activities taking part throughout the entire four-week course. The materials used during the course included: anatomy books and atlases, which we used to compare theoretical knowledge we had already acquired at University of Palermo with the body structures studied on the cadaver; surgical attire (scrubs) we wore every day in the dissection hall; latex gloves; surgical instruments, such as toothed forceps, anatomical forceps, #22 scalpel blades and #4 handles, Mayo scissors, blunt dissection scissors (these materials were acquired by the participants), vascular clamps, and rib shears (provided by the UoM).

3. Results and discussion

The dissection of the thorax was started with the cadaver lying supine on the dissection table with a support under the shoulders, allowing the hyperextension of the neck to expose the region of interest.

The technique used was the “layer-by-layer dissection”, that enabled us to separate and examine all the different layers one by one:

1. First incision;
2. Separation of cutaneous and subcutaneous tissue;
3. Removal the muscular layers;
4. Accessing the thoracic cavity;
5. Heart dissection.

A scalpel (blade #22, handle #4) was used to make the first incision from one shoulder to the contralateral one (biacromial incision). A midline incision was then carried out from the middle of the first incision to the pubic tubercle, passing at 3-4 cm from the umbilicus.

Then, using toothed forceps and the scalpel, the cutaneous and subcutaneous layers of the neck and thorax were separated from the muscular fasciae, exposing the pectoralis major and the superficial muscles of the neck. To achieve such separation, the cutaneous layer held with the forceps and, with the tip of the scalpel, following the separation line of the tissues, slight pressure was applied while moving the scalpel downwards, keeping the blade parallel to the surface of the underlying tissue.

The dissection was resumed by cutting the distal attachments of the pectoralis major, and reflecting it laterally. A half-moon shaped cut was carried out on the sterno-costal attachments, with the blade perpendicular to the surface, and the clavicular insertion was incised allowing the muscle to be reflected onto its omal attachment.

This enabled us to visualize the sternum, the medial part of the ribs, and the pectoralis minor.

The pectoralis minor was dissected using the same technique used for the pectoralis major: its attachments on the 3rd, 4th, and 5th ribs were incised, and with a combination of traction and section, the muscle was gradually separated from the ribs, and reflected onto its attachment on the coracoid process.

To gain access to the thoracic cavity, the muscles of the cervical region that attach to the sternum and the clavica (the two heads of the sternocleidomastoid, the sternothyroid and thyrohyoid, and the subclavian muscles) had to be reflected. Then, in order to disarticulate the clavica medially, a half-moon shaped incision was made with the scalpel along the sternoclavicular articular surface, cutting the articular capsula and the ligaments (anterior and posterior sternoclavicular, interclavicular, and costoclavicular ligaments) and, with a brisk movement, the clavica was disarticulated.

The last step to access to the thoracic cavity was removing the sternocostal triangle, made up by the sternum, and attached to the medial

portions of the costal cartilage. The rib shears were used to separate each rib from the costal cartilage, proceeding from the 10th to the 1st, keeping at a distance of 1-2 cm from the chondrocostal line.

Once the ribs were detached, the sternocostal triangle was lifted and the superior and inferior sternopericardial ligaments, which attach and anchor the pericardium to the anterior thoracic wall, were incised (Figure 1).

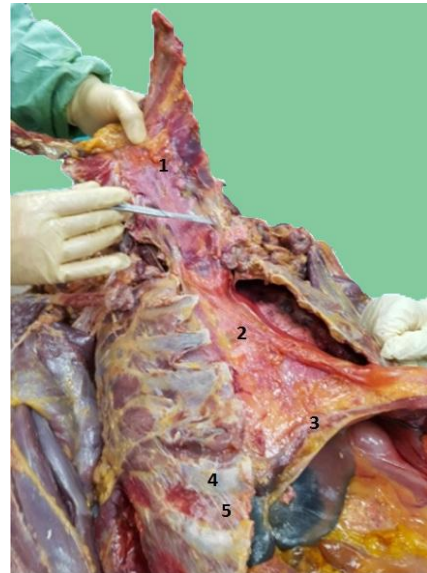

Figure 1 - Opening of the thoracic cage: 1) Sternal triangle 2) Superior and inferior sternopericardial ligaments 3) Diaphragm 4) Rib 5) External intercostal muscle

In order to proceed with the examination of the heart, the pericardial sac was opened (Figure 2) making a keyhole incision in the lower portion of the sac with toothed forceps, and then carrying out a "y-shaped incision" (one oblique incision to the left, one to the right and one along the acute margin of the heart) with Mayo scissors, while lifting the surface of the sac with the forceps. The opening allowed us to observe the anterior surface of the heart (Figure 3).

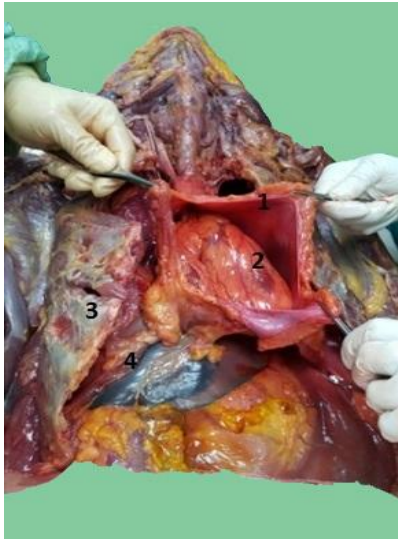

Figure 2 - Opening of the pericardial sac: 1) Pericardial sac 2) Left ventricle 3) Rib 4) Diaphragm

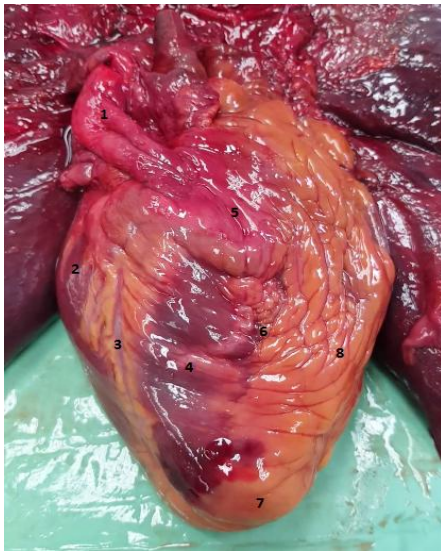

Figure 3 - Anterior surface of the heart: 1) Aortic arch 2) Right atrium 3) Coronary sulcus and right coronary artery 4) Right ventricle 5) Conus artery 6) Anterior interventricular sulcus and anterior interventricular branch of the left coronary artery 7) Cardiac apex 8) Left ventricle

There are several ways to carry out a heart dissection. The heart is usually dissected after formalin treatment, that would have required more time than we had. Therefore, we chose to dissect the heart immediately preserving the organ anatomy, in order to be able to study it once finished.

The dissection was started from the right side, observing the superior (SVC) and inferior vena cava (IVC) and, with clean cut using blunt scissors, the inner part of right atrium and, in particular, the foramen

ovale were exposed. The latter is one of the two fetal cardiac shunts, the second one being the ductus arteriosus, located between the pulmonary artery and the aorta for bypassing the pulmonary circulation in utero. The foramen ovale allows blood to enter the left atrium from right one during fetal life, and on its lower region we could observe the Eustachian valve, which controls the afflux of blood from the IVC, allowing oxygenated blood to pass through the foramen ovale in the fetal heart.

At the base of the IVC there is the coronary sulcus with its semilunar fold, the Thebesian Ring, that stops blood reflux through coronary sinus during atrial systole. These two valves are near to each other and they are linked by a fibrous band, known as the tendon of Todaro. This forms the apex of Koch's Triangle (a point of reference for the sinoatrial node), together with the insertion of the tricuspid valve.

In the right atrium, we could observe the pectinate muscles that form the auricular myocardium.

Carrying out a vertical cut, 1 cm to the right from the interventricular septum, to preserve the papillary muscles (Figure 4), the inner part of the right ventricle was exposed. The papillary muscles are attached to the ventricular wall and the cusps of the atrioventricular valves via the chordae tendineae (three in the tricuspid valve and two in the mitral valve). Their task is to allow perfect closure of the cusps, avoiding the blood regurgitation and valve prolapse.

These muscles can be considered the first type of trabeculae carneae. The second type of trabeculae carneae are fixed only at their extremities but free in the middle, like a bridge. The third type are fixed to the heart wall along their entire length.

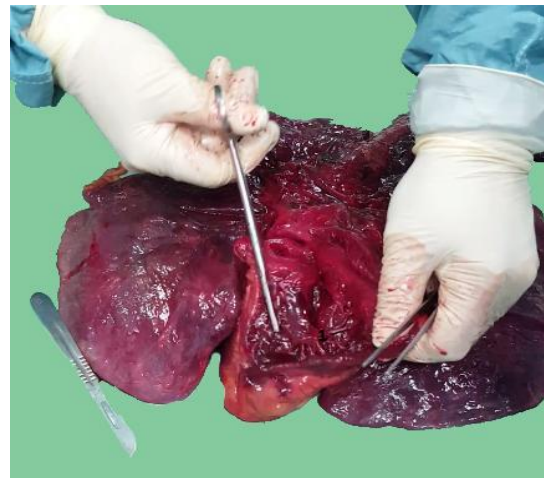


Figure 4 - Opening of the right ventricle: 1) Showing papillary muscles of the right ventricle.

The section on the trasversal plane highlights the difference between the left and right ventricle walls: the wall of left ventricle is thicker than the right one. This difference is due to the functional requirement for creating higher pressure in the left ventricle allowing blood to pump through the aorta to guarantee systemic circulation.

After analyzing the anatomy of the cardiac chambers, we focused on the vascularisation.

To expose the coronary arteries, blunt dissection forceps were used to remove the epicardial adipose tissue and isolate each coronary artery and branch from the underlying muscular tissue.

The left and right coronary arteries originate from the left anterior and posterior aortic sinus. The arteries form an anastomotic circle that is very variable and usually, in physiological conditions, unimportant. The rate of anastomosis becomes significant in case of hypoxia and stenosis of the coronary arteries.

The main coronary arteries and their branches are usually in a subepicardial position, but the ones that run on the interventricular sulcus are deeper. Usually there is a dominant artery that emits the posterior interventricular branch and perfuses the posterior part of the interventricular septum. In 60% of people the dominant artery is the right coronary.

We began by isolating the left coronary artery (Figure 5).

It originates from the left coronary sinus and vascularises most of the left ventricle, all the left atrium and much of the interventricular septum. The first tract runs between the left auricula and the pulmonary trunk, emerging in the atrioventricular sulcus and turns left.

The left coronary artery forms three main branches: anterior interventricular coronary artery, left marginal artery and the circumflex artery.

The anterior, or descending, interventricular artery could be considered as a continuation of the left coronary artery. It runs on the anterior interventricular sulcus and reaches the apex, often turning around the apex in the posterior interventricular sulcus. From the anterior interventricular artery originate the left and right anterior ventricular branches. The right ones are small and not more than two. The left ventricular arteries are bigger and emerge with an acute angle. One of these, often thicker than the other ones, is the diagonal artery, present in about 50% of people.

The left conus artery (Figure 6) is a branch which originates from the anterior interventricular artery, and anastomoses with the right conus artery and with the vasa vasorum of the aorta and pulmonary trunk.

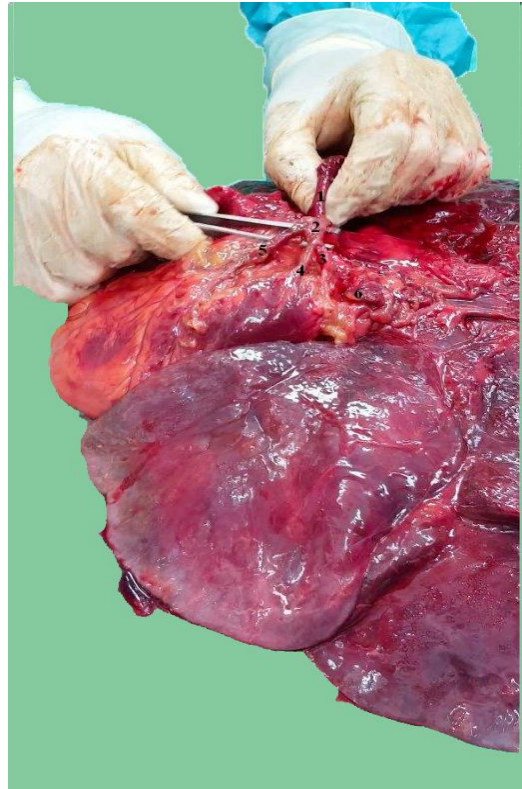


Figure 5 - Vascular elements: 1) Aorta 2) Left main coronary artery 2) Circumflex branch 3) Obtuse margin branch 4) Anterior descendant artery 5) Left auricula

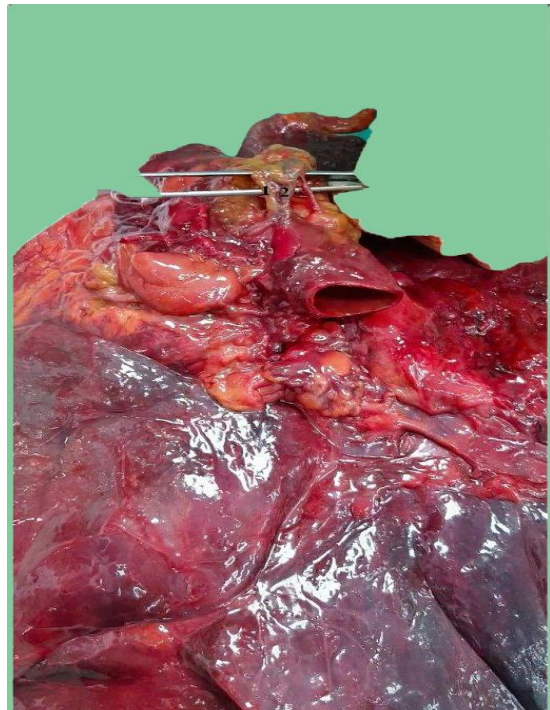


Figure 6 - Vascular elements: 1) Conus artery 2) Right coronary artery.

The anterior septum branches, which perfuse the ventral 2/3 of the septum also originate from the anterior interventricular artery. There are also some small posterior branches of the septum, that originate from the variable-length portion of interventricular artery that runs beyond the apex.

The circumflex artery runs on the left atrioventricular sulcus, passing over the obtuse margin of the heart and on the posterior atrioventricular sulcus, ending on the left side of the crux cordis. In most cases, from the circumflex artery originates the left marginal artery, that follows the obtuse margin and perfuses most muscles of the left ventricle. The circumflex artery gives rise to small variable branches: the anterior ventricular branches, that replace the diagonal artery when absent; the small posterior ventricular branches; the sinoatrial node artery, that usually originates from the anterior atrial branch of the right coronary artery, although it can also originate from the circumflex artery in 35% of people (usually the anterior tract).

The atrioventricular node artery, a branch of the posterior interventricular artery, can originate, in case of left-side dominance, from the circumflex artery.

The right main coronary artery originates from the anterior aortic sinus. It first runs on the right side between the right auricula and the pulmonary trunk, and then descends along the atrioventricular sulcus to the right margin of the heart, turning around it to continue in the posterior part of the sulcus into the crux cordis, which is the intersection between the posterior interatrial and interventricular sulcus. The artery ends at the left of the crux, usually anastomosing with the left circumflex branch of the left coronary artery.

The branches of the right coronary artery perfuse the right atrium and ventricle, and part of the septum and the left chambers.

The first branch is the conus artery, that can also originate independently from the ascending aorta. It branches between the top of the right ventricle and the base of the pulmonary trunk, and can anastomose with the equivalent branch of the left coronary, which comes from the anterior descending artery, forming an anastomotic circle that surrounds the right ventricle afflux conus, known as Vieussens's ring.

Other branches of the main right coronary artery are the anterior atrial and ventricular branches.

The atrial branches can be divided into anterior and lateral, which usually perfuse the right atrium, and the posterior branch, which perfuses both atriums.

The ventricular branches are usually two or three, and emerge at a 90° angle. They perfuse the anterior part of the right ventricle, heading towards the apex of the heart, but not reaching it.

Another branch of the right main coronary artery is the marginal coronary artery, which follows the acute margin of the heart, reaching the apex in most people.

From the posterior segment of the right main coronary artery originate up to three small posterior ventricular branches that perfuse the diaphragmatic facet of the heart, and one to three posterior interventricular branches. One of these is the posterior interventricular artery which, in most cases, runs alone on the interventricular sulcus.

The sinoatrial node artery can have a variable origin: in most cases, it originates from the anterior atrial branch, but it can also originate from the circumflex branch of the left coronary artery.

This artery runs between the right auricula and the aorta and, at the base of the superior vena cava, it forms small branches directed to the right

atrium, and a bigger branch for the sinoatrial node called ramus cristae terminali.

The posterior part of the interventricular septum is perfused by the septum branches that originate from the posterior interventricular artery. Usually, the larger one reaches the sinoatrial node.

4. Conclusion

This article highlights the benefits of a more practical approach to anatomical studies, involving cadaver dissections as a secondary step following theoretical studies. Participating in the dissection course allowed us to improve our anatomical knowledge, enabling us to compare each actual body structure with the theoretic information previously acquired from books. Despite our excellent grades in the anatomy exam, being faced with a real human body, at first, we were totally disoriented while trying to pinpoint specific body structures, such as vessels or nerves. We were too used to thinking of arteries as red, veins as blue and nerves as yellow, since that is how they are pictured in most anatomy books and atlases. Only after practise and real-life experience, we finally became able to apply all the theoretical knowledge acquired previously. We hope that in the future, such opportunities will be offered to all medicine students, because only through combining theory with practise can the future of medicine have no limits.

5. Acknowledgements

We would like to thank professor Francesco Cappello from the UoP for enabling this collaboration with the UoM, and giving us such a remarkable opportunity to enhance our studies.

References

1. Costantino C, Maringhini G, Albegiani V, Monte C, Lo Cascio N, Mazzucco W. Perceived need for an international elective experience among Italian medical residents. *EuroMediterranean Biomedical Journal* 2013, 8 (3):10-15.
2. Mazzucco W, Marotta C, de Waure C, Marini G, Fasoletti D, Colicchio A, Luppi D, Pignatti F, Sessa G, Silenzi A, Puccio G, Parente P, Costantino C, Bonetti P, Gangi S, Maffongelli E, Nania R, Russo S. Motivational aspects and level of satisfaction of Italian junior doctors with regard to knowledge and skills acquired attending specific general practice training courses. A national web survey *EuroMediterranean Biomedical Journal* 2017, 12 (17):77-86
3. Etrusco A, Salvaggio L, Arrigo G, Cataldi S, Farina C, Gattuso I, La Bruna M, Pistone M, Tinaglia S, Torregrossa F, Carini F, Tomasello G, Pomara C. Anatomical dissection and analysis of the structures of the upper limb. *EuroMediterranean Biomedical Journal* 2017, 12 (4):13-16.
4. Costantino C, Moscadini S, Puccio G, Cappello F, Mazzucco W. *EuroMediterranean biomedical journal: The renewed manuscript layout and web rendering foreshadow further journal improvement.* *EuroMediterranean Biomedical Journal* 2017, 12 (1): 1-5

-
5. Costantino C, Moscadini S, Puccio G, Cappello F, Mazzucco W. EuroMediterranean biomedical journal: The renewed journal for young doctors aims even higher. *EuroMediterranean Biomedical Journal* 2014, 9 (1): 1-6.
 6. Anastasi G, Capitani S, Carnazza ML, Cinti S, De Caro R, Donato RF, Ferrario VF, Fonzi L, Franzi AT, Gaudio E, Geremia R, Lanza GG, Grossi CE, Gulisano M, Manzoli FA, Mazzotti G, Michetti F, Miscia S, Mitolo V, Montella A, Orlandini G, Paparelli A, Renda T, Ribatti D, Ruggeri A, Sirigu P, Soscia A, Tredici G, Vitale M, Zaccheo D, Zauli G, Zecchi S. *Anatomia Umana - Trattato. Volumi 1-3. Edi-Ermes IV edizione.*
 7. Standring S. *Anatomia del Gray. Le basi anatomiche per la pratica clinica.* Elsevier 2009.
 8. Pomara C, Karch SB, Fineschi V. *Forensic Autopsy: A Handbook and Atlas.* CRC Press 2010.