

TIBIO-FIBULAR BONE TRANSPOSITION FOR THE TREATMENT OF ONCOLOGICAL PERIPROSTHETIC INFECTION OF THE KNEE WITH MASSIVE BONE LOSS

Raffaele Pezzella ¹, Arnaldo Filippini ², Mariano Giuseppe Di Salvatore ¹, Antonio Medici ¹, Giuseppe Toro ³, Giandomenico Logroscino ⁴, Vittorio Calvisi ⁴.

1. Unit of Orthopaedics and Traumatology, AORN S. Giuseppe Moscati, Avellino, Italy

2. Department of Medicine and Aging Sciences, University of Chieti "G. D'Annunzio". Chieti, Italy

3. Department of Medical and Surgical Specialties and Dentistry, University of Campania "Luigi Vanvitelli", Naples, Italy

4. Department of life health & environmental sciences" University of L'Aquila, Unit of Orthopaedics and Traumatology - L'Aquila (Italy).

ARTICLE INFO

Article history:

Accepted 12 Jul 2021

Revised 13 Sep 2021

Published 05 Oct 2021

Keywords:

Transfemoral amputation,
megaprosthesis infection, Stump
lengthening, bone sarcoma.

ABSTRACT

Chronic periprosthetic joint infection (PJI) is one of the most relevant complications in orthopaedic surgery, especially in the case of limb reconstruction with megaprotheses after malignant tumoral resection. This is the report of a case of a 35-year-old patient, affected by a chronic PJI around a knee megaprosthesis implanted after the resection of an osteosarcoma of the distal femur. "En bloc" resection and limb reconstruction with an expandable megaprosthesis of the knee were performed at the age of 5 years old (1989). PJI occurred after the definitive megaprosthesis implantation (2002), and became chronic over the years.

In 2019, due to a massive recrudescence of the infection and the severe femoral bone loss, the patient underwent a wide intercalary resection and a thigh stump reconstruction by transposition of the fibula and the distal third of the tibia in order to avoid a hip disarticulation.

Although complex, the proposed treatment allowed improved outcomes in a young patient with high function requests, justifying the global surgical invasiveness.

© EuroMediterranean Biomedical Journal 2021

who are often immunocompromised by chemotherapy and radiotherapy (7,9).

1. Introduction

Limb-salvage surgery for primary malignant bone tumors has become a gold standard. Oncological megaprosthesis after wide local excision, combined with neoadjuvant chemotherapy and/or radiotherapy (1–3) is one of the more reliable options. Thanks to improved surgical techniques and new devices, salvage surgery is applicable in up to 85% of patients resulting in limb salvage in up to 90% of them (4).

The advantages of prosthetic reconstruction include quick functional recovery as well as good long-term function. The disadvantages include a higher failure risk due to infection, mechanical failure and aseptic loosening (range: 25% to 92%) (5–8).

The high rate of early periprosthetic joint infection (PJI) around an oncological megaprosthesis is related to the massive bulk of the implant, the long operative time and the extensive soft-tissue exposure in patients

Oncological PJI might be a devastating complication and may require limb amputation (30% in the Furtado *et al.* series (10) even after several years from the prosthesis implantation (11). These amputations were often undertaken after several failed attempts to eradicate the infection with antibiotic therapy (10).

Several treatment options had been proposed, mostly challenging and with unsatisfactory outcomes. Limb amputation with short proximal stump and hip disarticulation are among the procedures with the poorest outcomes.

* Corresponding author: Raffaele Pezzella, raffaelepezzella008@gmail.com

DOI: 10.3269/1970-5492.2021.16.30

All rights reserved. ISSN: 2279-7165 - Available on-line at www.embj.org

2. Material and methods

This report describes the case of a 35-year-old patient affected by chronic oncological PJI of the knee that occurred around a megaprosthesis implanted for osteosarcoma (Fig. 1) of the distal femur.

In 1989, the patient underwent “En bloc” resection of the distal femur and proximal tibia, on safety margins, and to limb reconstruction with expandable megaprosthesis (Fig. 2).

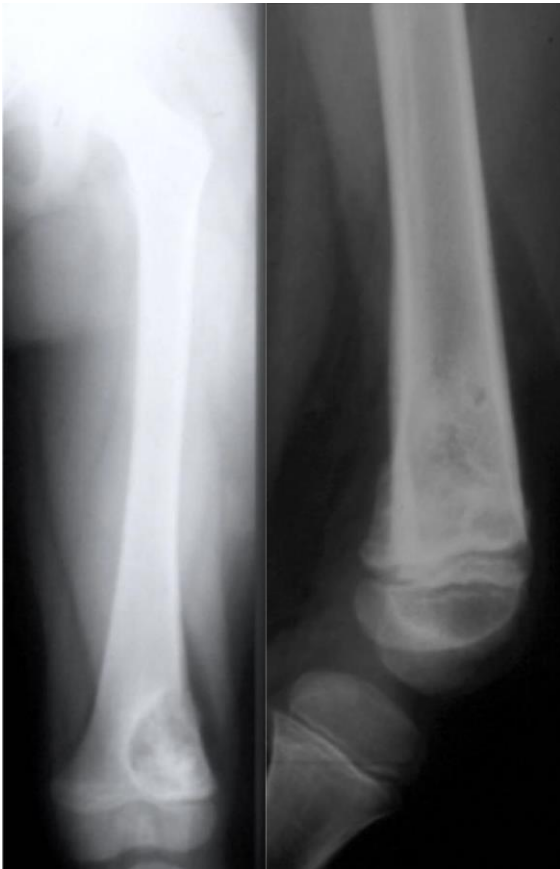

Figure 1. The neoplastic lesion at the beginning in October 1988

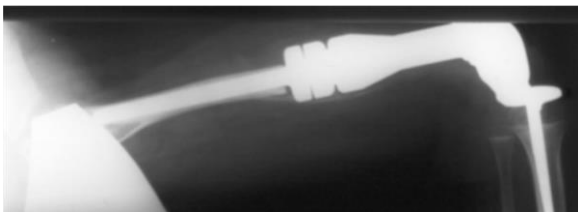


Figure 2. Expandable prosthesis at the time of implantation in 1989

A specific neoadjuvant and adjuvant chemotherapy was also started after tumor resection. During the following years the patient underwent various procedures in order to expand the megaprosthesis to assure limb length throughout the developmental age (Fig. 3). In 2002, a definitive knee custom made megaprosthesis with a femoral and tibial long stem was implanted. 3 months after the last surgery the patient started to complain of knee pain, limited function, swelling and developed a secreting fistula.

An infection sustained by a methicillin-resistant *Staphylococcus Aureus* was detected. Several unsuccessful attempts to eradicate the infection were performed during the following years surgically (1 DAIR, 1 one – stage, 5 two stage revision, 2 local muscular flap) and pharmacologically. Therefore, a chronic suppressive antibiotic therapy (based on 1 × 160/800 mg Trimethoprim/Sulfamethoxazole tablet 3 times/day and 1 × 100 mg Minocycline tablet twice/day) was started from August 2016. A remission of the clinical signs of infection was achieved but without complete negativity of the serum biomarkers of infection erythrocyte sedimentation rate (ESR) and C reactive protein (CRP). In September 2018, a new recrudescence of the infection with appearance of a new fistula occurred. Obviously, the serum biomarkers started to increase constantly from that date.

X – Rays performed at that time showed a wide bone resorption of the proximal femur while the remaining part of the bone was occupied by both the bone cement and the prosthetic stem (Figures 4 – 5).

Moreover, an impressive alteration of the bone structure of the tibia up to the middle third was also observed. The tibial stem was displaced posteriorly, infixed into the posterior part of the tibial shaft. Considering the poor bone quality and the presence of an active infection, the patient decided to undergo lower limb amputation. However, to avoid a hip disarticulation or a very high transfemoral resection, an intercalary trans-knee resection was performed. Subsequently, to improve the length of the femoral stump, a turn-up vascularized fibula and vascular tibial pilon were planned by a multidisciplinary team composed of 3 orthopedics and 1 plastic surgeon.

Surgical procedure.

The patient was in supine position, all the fistula traits were removed and the megaprosthesis was explanted using a large surgical approach. An aggressive debridement of the remaining periprosthetic tissues was performed. The cement was carefully removed from both the femoral and tibial canals and an amputation of the tibio-astragalic joint was also performed.

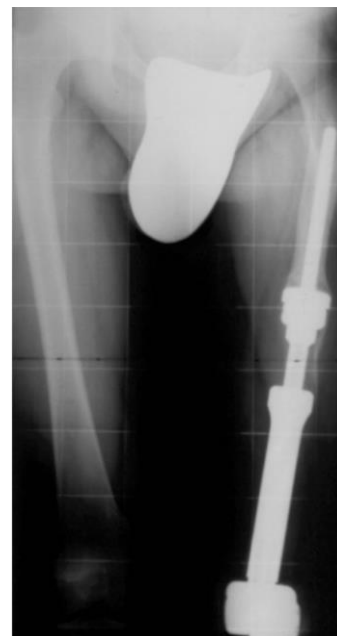

Figure 3. Expandable prosthesis in the elongation stage

A vascularized fibula bone graft was then prepared and grafted by turning it proximally and introduced within the femoral shaft.

In order to increase the strength of the distal femoral stump, the tibial pilon was also isolated within its vascular axis, turned proximally and fixed to the fibula with two cortical lag screws. The adductor muscles were attached to the lateral part of the tibia. Finally, a reconstruction of the anterior portion of the thigh was performed using the posterior leg muscles to provide an adequate muscular coverage of the distal bone surfaces (Fig 8).

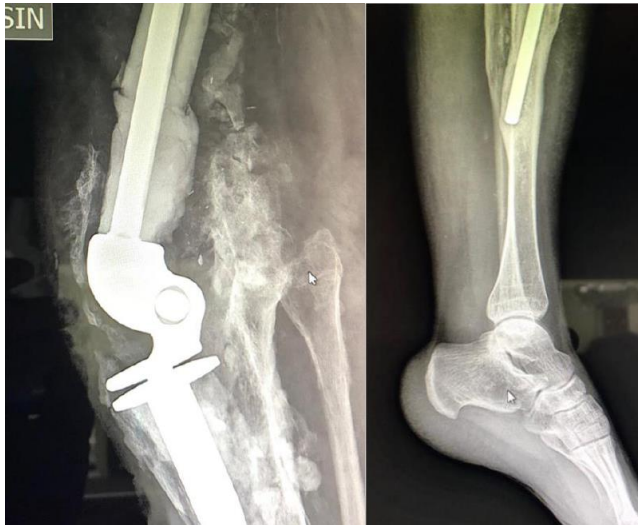
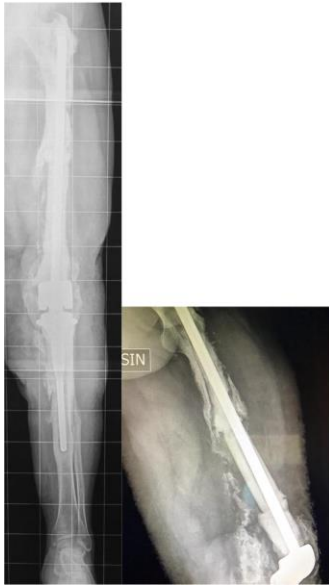
Figure 4-7. The condition of the implant when decided for the amputation

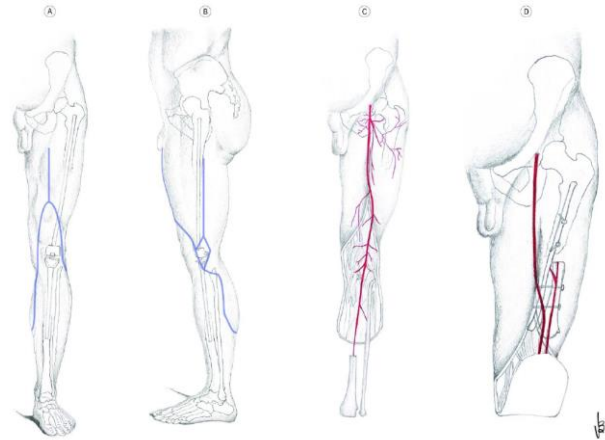


Figure 8. Schematic representation of surgery.

Post-operative protocol and follow-up.

An antibiotic therapy (1 × 600 mg Linezolid tablets twice/day) was started just after the surgery and prolonged for up to 8 weeks. A specific rehabilitation protocol was started since the discharge from the hospital. Clinical and X-ray evaluations were performed every 3 months. Wound healing was achieved without major complications and the definitive prosthesis was dressed 10 weeks after the surgery. Full weight-bearing walking was allowed at 8 weeks after surgery. The patient returned to his work as an orthopedic surgeon 4 months after the surgery (Fig. 6). At the last follow-up, after 18 months, an excellent osteointegration without signs of resorption of the graft were observed. Clinically, the patient showed a good functional recovery (Fig 9.) measured with SF12 (PCS-12 (Physical Score): 53.1879|MCS-12 (Mental Score): 60.17871) and Berg Balance Scale (50 pt) without any sign of recurrence of the infection. An RX evaluation of fibula integration is yet to be assessed at six months (fig. 10) and at two years (fig.11).

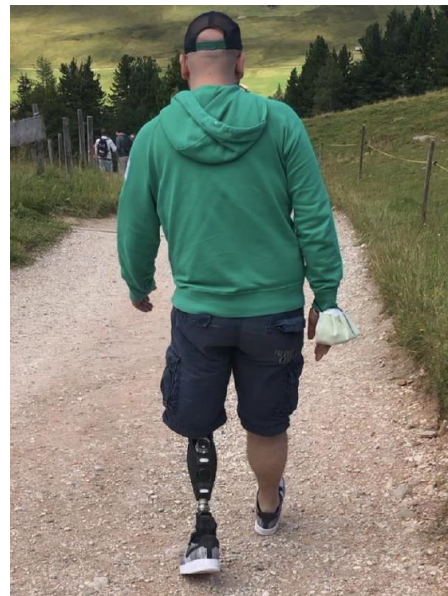

Figure 9. Daily activity at 18 months after surgery

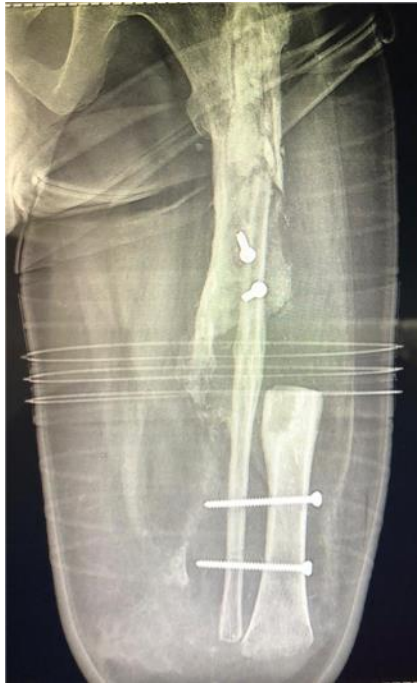

Figure 10. RX at six months after surgery

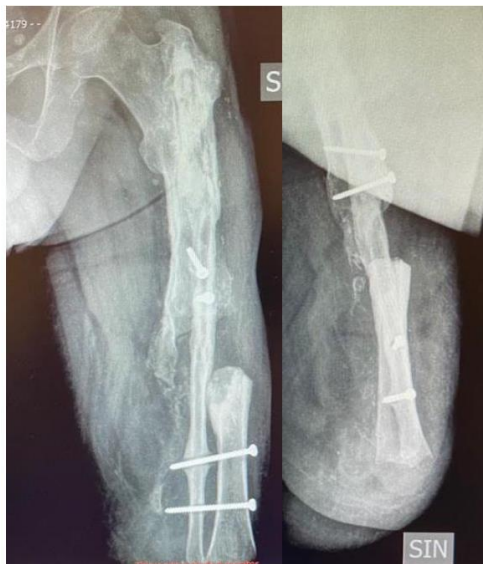

Figure 11. RX at two years after surgery in AP and LL

3. Discussion

Oncological PJI was reported as the most common reason of prosthetic failure (8.3%) in a meta-analysis conducted by Henderson *et al.*(12). The treatment of oncological PJI is very demanding both for the patient, who faces very debilitating physical and psychological conditions, and the surgeon(13). Moreover, the occurrence of an early infection may also delay the adjuvant chemotherapy administration and require further surgical procedures.

Grimer (11) stated that the overall oncological megaprosthesis infection rate at 25 years was 26%, which is greater than the one described by any other author, including the previously reported infection rate of 11% (6,9,14). Jeys *et al.* assessed that the risk of infection does not decrease with time, but it remains unaltered at approximately 1% x year of megaprosthesis life(14,15).

Although total femur endoprosthesis (TFEPR) was considered a reliable option(16) for reconstruction of massive femur bone loss, and with satisfactory survivorship, we decided not to perform a two-stage revision with a TFEPR, to avoid a massive disruption of the proximal femur that might have impaired the use of a subsequent external prosthesis in case of limb amputation. In fact, TFEPR presented a high complication related mainly to age at initial reconstruction (16,17).

In case of oncological PJI of the knee, the amputation is a very effective and valid option. In these cases, the length of the stump is crucial for the final outcome. Several techniques for the creation of longer stumps have been described including the turn-up bone flap technique for the below-knee lengthening, and the femoral elongation by distractive external fixation(18–20).

In the present case report, considering the multiple unsuccessful surgical treatments to treat osteomyelitis (>10) and the patient's needs, we chose to provide infection eradication and stump elongation in a single-step surgery based on an intercalary, interjoint resection and reconstruction of a longer thigh stump with the rotation of a vascularized fibular graft augmented by a tibial one.

There are several theoretical advantages of a one-stage reconstruction: (1) the achievement of bone loss reconstruction and soft-tissue coverage of the stump at the same time; (2) prevention of adjacent soft-tissue and recipient vessel scarring and reduction of surgical trauma on soft tissues; (3) reduction of the need of repeated microvascular tissue transfers; (4) early bone structural stability; (5) promotion of bone union; (6) eradication of the infection; (7) reduction of the overall healing time of severe complex injuries of the lower extremities (15).

The length of the residual femur substantially influences proprioception and gait kinematic following transfemoral amputation, and it seems to be a prominent factor over femoral orientation to patients' outcomes. Furthermore, the patient suffered a massive loss of muscle tissue, due to tumor radical excision and to the several surgical treatments. Therefore, we decided to create a longer stump that allowed an improved function, fit and comfort of the prosthesis.

In fact, several authors underlined that the length of the stump positively correlates with the energy expenditure of the patients and with the best fit and functionality of the external prosthesis (21–28). Moreover, an increased residual limb length is more beneficial for gait parameters, prevention of contractures and improvement of the lever arm(29).

The rotation of the vascularized bone grafts was preferred for the stump reconstruction because they had a lower risk of resorption, present good mechanical strength that allow for rapid bearing, are more resistant to infection, and are associated with rapid remodeling and hypertrophy (30–32)

Moreover, the use of a myodesis with the insertion of the distally detached adductor magnus muscle to the lateral femoral bone, resulted in a stronger stump with good muscle balance, and an improved prosthetics fitting, as previously reported (21).

Long bone reconstruction using an autologous vascularized fibular graft is a reliable technique providing satisfactory functional results. The fibula flap has a lower infection rate than traditional allograft reconstruction. There is a high rate of bone union, and functional outcome is good. (33–37)

To the best of our knowledge, this is the first description of a technique of reconstruction of the femoral bone length through the rotation of the fibula and the tibial pylon on their vascular peduncle.

4. Conclusions

Although the described technique is technically demanding and requires long operating time and a highly qualified surgical team, the reconstruction of a longer thigh stump through the rotation of the fibula and the tibial pylon on their vascular peduncle was effective and reliable, assuring good and long-lasting functional results, thus improving the patient's quality of life. Obviously, the standardization of the proposed technique needs larger cohort studies.

References

1. Yang Y, Han L, He Z, Li X, Yang S, Yang J, et al. Advances in limb salvage treatment of osteosarcoma. *J Bone Oncol*. marzo 2018;10:36–40.
2. Ueda T. UT. Development of Multidisciplinary Approach for Bone and Soft-tissue Sarcomas in Japan. *Austral - Asian J Cancer*. gennaio 2010;9(1):27–40.
3. Bielack SS, Hecker-Nolting S, Blattmann C, Kager L. Advances in the management of osteosarcoma. *F1000Research*. 25 novembre 2016;5:2767.
4. De Gori M, Gasparini G, Capanna R. Risk Factors for Perimegaprothetic Infections After Tumor Resection. *Orthopedics [Internet]*. gennaio 2017 [citato 30 maggio 2021];40(1). Disponibile su: <http://journals.healio.com/doi/10.3928/01477447-20161128-01>
5. Capanna R, Morris HG, Campanacci D, Del Ben M, Campanacci M. Modular uncemented prosthetic reconstruction after resection of tumours of the distal femur. *J Bone Joint Surg Br*. marzo 1994;76(2):178–86.
6. Jeys L, Grimer R. The Long-Term Risks of Infection and Amputation with Limb Salvage Surgery Using Endoprostheses. In: Tunn P-U, curatore. *Treatment of Bone and Soft Tissue Sarcomas [Internet]*. Berlin, Heidelberg: Springer Berlin Heidelberg; 2009 [citato 30 maggio 2021]. pag. 75–84. (Recent Results in Cancer Research; vol. 179). Disponibile su: http://link.springer.com/10.1007/978-3-540-77960-5_7
7. Capanna R, Scoccianti G, Frenos F, Vilardi A, Beltrami G, Campanacci DA. What Was the Survival of Megaprotheses in Lower Limb Reconstructions After Tumor Resections? *Clin Orthop*. marzo 2015;473(3):820–30.
8. Sharma S, Turcotte RE, Isler MH, Wong C. Experience with Cemented Large Segment Endoprostheses for Tumors. *Clin Orthop*. giugno 2007;459:54–9.
9. Jeys LM, Kulkarni A, Grimer RJ, Carter SR, Tillman RM, Abudu A. Endoprosthetic Reconstruction for the Treatment of Musculoskeletal Tumors of the Appendicular Skeleton and Pelvis: *J Bone Jt Surg*. giugno 2008;90(6):1265–71.
10. Furtado S, Grimer RJ, Cool P, Murray SA, Briggs T, Fulton J, et al. Physical functioning, pain and quality of life after amputation for musculoskeletal tumours: a national survey. *Bone Jt J*. settembre 2015;97-B(9):1284–90.
11. Grimer RJ, Aydin BK, Wafa H, Carter SR, Jeys L, Abudu A, et al. Very long-term outcomes after endoprosthetic replacement for malignant tumours of bone. *Bone Jt J*. giugno 2016;98-B(6):857–64.
12. Henderson ER, Groundland JS, Pala E, Dennis JA, Wooten R, Cheong D, et al. Failure Mode Classification for Tumor Endoprostheses: Retrospective Review of Five Institutions and a Literature Review. *J Bone Jt Surg*. 2 marzo 2011;93(5):418–29.
13. Racano A, Pazonis T, Farrokhyar F, Dehesi B, Ghert M. High Infection Rate Outcomes in Long-bone Tumor Surgery with Endoprosthetic Reconstruction in Adults: A Systematic Review. *Clin Orthop*. giugno 2013;471(6):2017–27.
14. Jeys LM, Grimer RJ, Carter SR, Tillman RM. Periprosthetic Infection in Patients Treated for an Orthopaedic Oncological Condition: *J Bone Jt Surg*. aprile 2005;87(4):842–9.
15. Yazar S, Lin C-H, Wei F-C. One-Stage Reconstruction of Composite Bone and Soft-Tissue Defects in Traumatic Lower Extremities: *Plast Reconstr Surg*. novembre 2004;1457–66.
16. Toepfer A, Harrasser N, Petzschnher I, Pohlig F, Lenze U, Gerdesmeyer L, et al. Is total femoral replacement for non-oncologic and oncologic indications a safe procedure in limb preservation surgery? A single center experience of 22 cases. *Eur J Med Res*. dicembre 2018;23(1):5.
17. Medellin MR, Fujiwara T, Clark R, Stevenson JD, Parry M, Jeys L. Mechanisms of failure and survival of total femoral endoprosthetic replacements. *Bone Jt J*. maggio 2019;101-B(5):522–8.
18. Wade SM, Harrington C, Fleming M, Potter BK. A Combined Distal Tibial Turn-up Plasty and Intercalary Calcaneal Osteocutaneous Fillet Flap for Salvage of a Transtibial Amputation: A Case Report. *JBJS Case Connect*. dicembre 2017;7(4):e91–e91.
19. Pant R, Younge D. Turn-up bone flap for lengthening the below-knee amputation stump. *J Bone Joint Surg Br*. marzo 2003;85-B(2):171–3.
20. Polfer EM, Potter BK. Turn-up Plasty for Salvage of Transtibial Amputations: An Illustrated Description of the Surgical Technique: A Case Report. *JBJS Case Connect*. 23 dicembre 2015;5(4):e116.
21. Boonstra AM, Schrama J, Fidler V, Eisma WH. The gait of unilateral transfemoral amputees. *Scand J Rehabil Med*. dicembre 1994;26(4):217–23.

22. Walker JL, White H, Jenkins JO, Cottle W, VandenBrink KD. Femoral lengthening after transfemoral amputation. *Orthopedics*. gennaio 2006;29(1):53–9.
23. Bell JC, Wolf EJ, Schnall BL, Tis JE, Tis LL, Benjamin K, Potter M. Transfemoral Amputations: The Effect of Residual Limb Length and Orientation on Gait Analysis Outcome Measures. *J Bone Jt Surg*. 6 marzo 2013;95(5):408–14.
24. Bell JC, Wolf EJ, Schnall BL, Tis JE, Potter BK. Transfemoral Amputations: Is There an Effect of Residual Limb Length and Orientation on Energy Expenditure? *Clin Orthop*. ottobre 2014;472(10):3055–61.
25. Gottschalk F. The importance of soft tissue stabilization in trans-femoral amputation: English version. *Orthop*. marzo 2016;45(S1):1–4.
26. Gottschalk F. Transfemoral amputation. *Biomechanics and surgery*. *Clin Orthop*. aprile 1999;(361):15–22.
27. Baum BS, Schnall BL, Tis JE, Lipton JS. Correlation of residual limb length and gait parameters in amputees. *Injury*. luglio 2008;39(7):728–33.
28. Schnur D, Meier RH. Amputation Surgery. *Phys Med Rehabil Clin N Am*. febbraio 2014;25(1):35–43.
29. Geertzen JHB, de Beus MC, Jutte PC, Otten E, Dekker R. What is the optimal femur length in a trans-femoral amputation? A mixed method study: Scoping review, expert opinions and biomechanical analysis. *Med Hypotheses*. agosto 2019;129:109238.
30. Cutting CB, McCarthy JG. Comparison of Residual Osseous Mass Between Vascularized and Nonvascularized Onlay Bone Transfers. *Plast Reconstr Surg*. novembre 1983;72(5):672–5.
31. Lau RSF, Leung PC. Bone graft viability in vascularized bone graft transfer. *Br J Radiol*. maggio 1982;55(653):325–9.
32. Teissier J, Bonnel F, Allieu Y. Vascularization, Cellular Behavior, and Union of Vascularized Bone Grafts: Experimental Study in the Rabbit. *Ann Plast Surg*. giugno 1985;14(6):494–505.
33. Ceruso M, Falcone C, Innocenti M, Delcroix L, Capanna R, Manfrini M. Skeletal Reconstruction with a Free Vascularized Fibula Graft Associated to Bone Allograft After Resection of Malignant Bone Tumor of Limbs1. *Handchir · Mikrochir · Plast Chir*. luglio 2001;33(4):277–82.
34. Lee JE, Kim MB, Han D hwan, Pyo SH, Lee YH. One-Barrel Microsurgical Fibula Flap for Reconstruction of Large Defects of the Femur. *Ann Plast Surg*. aprile 2018;80(4):373–8.
35. Antonini A, Rossello C, Salomone C, Iacoviello P, Chiarlone F, Burastero G. Bone Defect Management with Vascularized Fibular Grafts in the Treatment of Grade III-IV Osteomyelitis. *Handchir · Mikrochir · Plast Chir*. dicembre 2019;51(06):444–52.
36. Laffosse J-M, Accadbled F, Abid A, Kany J, Darodes P, Sales de Gauzy J. Reconstruction osseuse des os longs après exérèse carcinologique par l'utilisation de greffons fibulaires vascularisés chez l'enfant et l'adolescent. *Rev Chir Orthopédique Réparatrice Appar Mot*. ottobre 2007;93(6):555–63.
37. Chen CM, Disa JJ, Lee H-Y, Mehrara BJ, Hu Q-Y, Nathan S, et al. Reconstruction of Extremity Long Bone Defects after Sarcoma Resection with Vascularized Fibula Flaps: A 10-Year Review. *Plast Reconstr Surg*. marzo 2007;119(3):915–24.