

## Case Report

# JUVENILE NASOPHARYNGEAL ANGIOFIBROMA: AN ENDOSCOPIC APPROACH WITH PRE-OPERATIVE EMBOLIZATION SUPPORTED BY NEURONAVIGATED COMPUTED TOMOGRAPHY

Cosimo Galletti <sup>1,\*</sup>, Agostino Tessitore <sup>2</sup>, Francesco Ciodaro <sup>1</sup>, Francesco Freni <sup>1</sup>, Antonio Pitrone <sup>2</sup>, Bruno Galletti <sup>1</sup>

1. Department of Adult and Development Age Human Pathology "Gaetano Barresi", unit of Otorhinolaryngology, University of Messina Messina ME, Italy;

2. Neuroradiology Unit, University Hospital A.O.U. "G. Martino", Messina, Italy.

### ARTICLE INFO

#### Article history:

Received 28 Mar 2022

Accepted 19 May 2023

Published 24 Jun 2023

#### Keywords:

ent, juvenile nasopharyngeal angiofibroma, endoscopic sinus surgery, epistaxis, selective embolization.

### ABSTRACT

The purpose of this clinical report is to present our surgery approach combined to the preoperative embolization and the follow-up management of a patient with a Juvenile Nasopharyngeal Angiofibroma (JNA). JNA is a relatively uncommon vascular benign neoplasm that affects almost exclusively adolescent males and represents 0.05% of all head and neck tumors with an incidence of 1:150,000. We present a case of a nineteen-year-old patient with severe and recurrent episodes of epistaxis in the last months. Nasal endoscopy showed a vascularized neof ormation that obliterate the right posterior nasal cavity and rhinopharynx. A skull computed tomography (CT) study with contrast medium showed a three centimeters soft tissue mass within the right posterior nasal cavity with extension to the homolateral pterygopalatine fossa and adjacent sphenoid sinus; a little forward bowing of the posterior wall of the right maxilla (Holman–Miller sign) was reported. An angiographic exam was performed, in the same time, was carried out an embolization of intense vascular supply of the mass. We decided to perform an endoscopic approach supported by neuronavigated computed tomography to remove the mass. The advance in the endoscopic surgery approach in cases of such complexity with the support of a neuronavigation system and the possibility to perform a pre-operative embolization lead to a change in the management of JNA now may be considered for endoscopic sinus-surgery removal.

© EuroMediterranean Biomedical Journal 2023

## 1. Introduction

We introduce a case of a nineteen-year-old patient with severe and recurrent episodes of epistaxis in the last months with a possible diagnosis of juvenile nasopharyngeal angiofibroma (JNA). JNA is a relatively uncommon vascular benign neoplasm that affects almost exclusively adolescent males and represents 0.05% of all head and neck tumors with an incidence of 1:150,000.

The common symptoms appears usually from 7 to 19 years, with an average age of 14 years. Typically, starting with nasal obstruction and epistaxis with a clinically aggressive characteristic tends to involve adjacent maxillary with a consequent facial deformity, palatal with palatal bulging, headache, otitis media, sinusitis, mastoiditis, and speech difficulty.[1 - 4].

A correlation with genetic alteration based on the development of JNA is the object of study and discussion, seems that a single theory can't explain all the characteristics of JNA. [5 - 6]

Preoperative diagnosis is centered on clinical and imaging evidence, the literature evidence that a preoperative CT study with contrast medium and/or MRI with contrast medium and angiography are essential to establish a correct extension and staging of the neof ormation. It's not recommended to perform an incisional biopsy cause may lead to important bleeding. [2]

In the literature are present numerous staging systems, the most extensive are by Chandler, Radkowski, and Andrews (modified Fisch). [1-4 , 7, 8]. The surgical treatment with resection is universally approved as the treatment of choice for JNA. Endoscopic transnasal resection is a widely accepted treatment for early-stage disease and is noted how to decrease morbidity.

\* Corresponding author: Cosimo Galletti, [cosimogalletti92@gmail.com](mailto:cosimogalletti92@gmail.com)

DOI: 10.3269/1970-5492.2023.18.16

All rights reserved. ISSN: 2279-7165 - Available on-line at [www.embj.org](http://www.embj.org)

In some hubs, endoscopic-assisted resection of advanced JNAs has also been described as showing good outcomes with the lowest long-term morbidity [9-14]. The change in a preoperative time performing an embolization of major feeding vessels to these tumors, commonly originating from the internal maxillary and ascending pharyngeal arteries, by interventional neuroradiologists has reported substantially less blood loss and improved the goal of the endoscopic resection. [15]

## 2. Case presentation

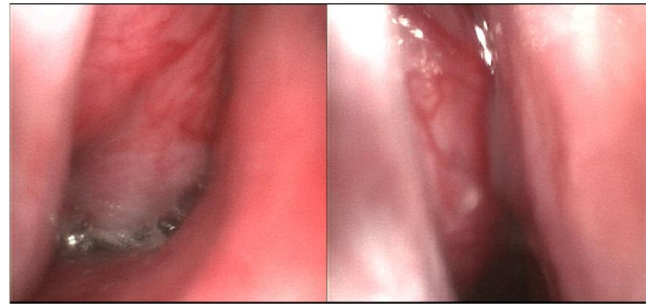
We present a case of a nineteen-year-old patient with a history of several episodes of epistaxis in the last months, the last episode requires positioning of a Merocell for any nasal cavity. Anamnesis mute for any previous diseases treated. He was admitted to our Otorhinolaryngology unit derived by another center. When the patient is stabilized, we decided to perform a rhino-fibro laryngoscopy with flexible optics evidencing a vascularized neformation that obliterates the right posterior nasal cavity and rhino pharynx (Figure 1).

A skull computed tomography study with contrast realized in the other center showed a three centimeters soft tissue mass within the right posterior nasal cavity with expansion to the homolateral pterygopalatine fossa and adjacent sphenoid sinus. The neuroradiologist noted the characteristic Holman-Miller sign, a little forward bowing of the posterior wall of the right maxilla.

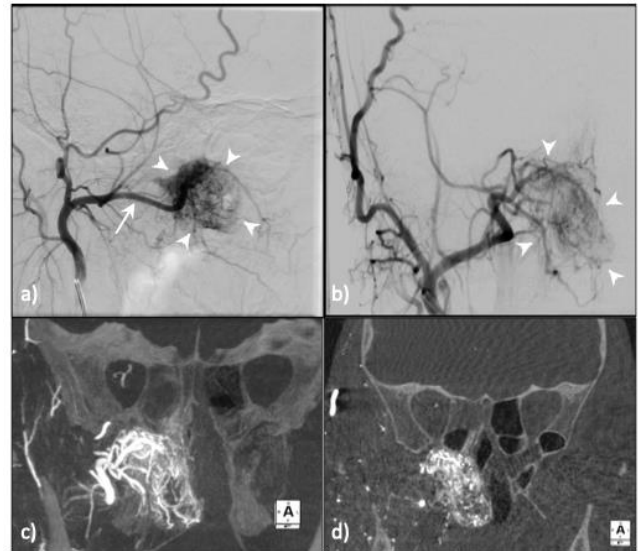
The diagnosis of presumption was JNA. According to the diagnosis, in agreement with the neuroradiologist, we decided to perform a Transfemoral angiographic exam of bilateral internal (ICA) and external (ECA) carotid arteries, performed with the patient in conscious sedation, showed intense contrast blush at right pterygopalatine fossa (Figure 2 a-b), which is supplied by sphenopalatine branches of the right internal maxillary artery, arising from the homolateral ECA system.

The angiographic study was integrated with an angiographic cone-beam CT (dyna-CTA) study of right ECA (Figure 2 c-d) that confirmed, especially with maximum intensity projection (MIP) reconstructions, the intense vascular supply of right nasopharyngeal mass. In the same endovascular time, in general anesthesia, with 6F guide catheter (6F Envoy – Codman Neuro) in the right external carotid artery and through a selective microcatheter 0.021 in (Headway 21 - MicroVention Inc.), was performed the embolization of each sphenopalatine branches of the right internal maxillary artery, using 250—355 microns particles of polyvinyl alcohol (Contour PVA Embolization Particles - Boston Scientific Corporation).

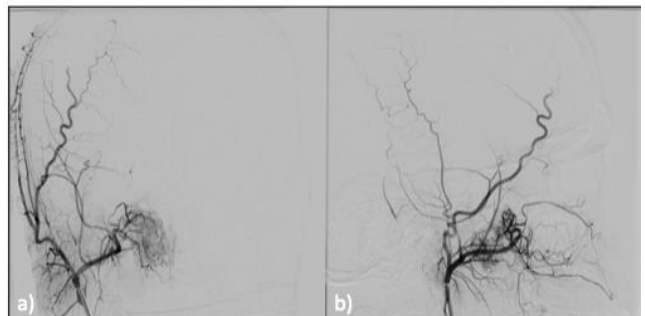
The angiographic result was a significant reduction of blood supply at the right nasopharyngeal mass (Figure 3). On the second day post-endovascular treatment was performed magnetic resonance imaging (MRI) that confirmed the right nasopharyngeal mass with low signal intensities on pre-contrast T1-weighted sequences and absence of contrast-enhancement (Figure 4) in the center of the lesion. An Endoscopic transnasal approach was performed with neuronavigated computed tomography a partial medial maxillectomy is done with a complete exeresis of the tumoral mass.



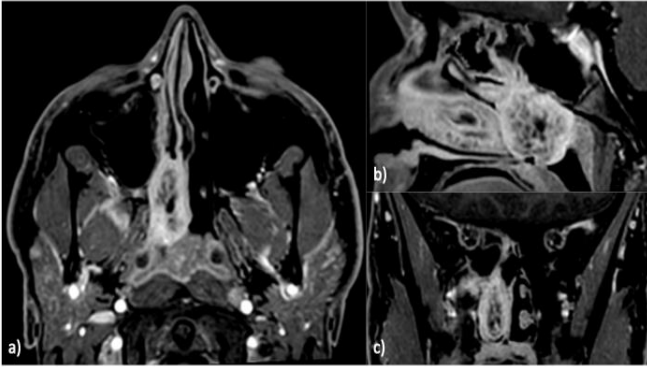
**Figure 1.** Flexible fiber optic examination showing a vascularized neformation that obliterates the right nasal fossa.



**Figure 2 a-d.** a-b) Digital Subtraction Angiography (DSA) of right ECA with lateral (a) and oblique (b) view, prior to embolization. The right external carotid angiography shows hypervascular tumor (arrowheads) with principal blood supply from sphenopalatine branches of the internal maxillary artery (arrow). c-d) Dyna-CTA study of right ECA – MIP reconstruction. Coronal (c) and para-coronal (d) view demonstrated the evident vascularization of the right nasopharyngeal mass.



**Figure 3 a-b.** Digital Subtraction Angiography (DSA) of right ECA with frontal (a) and lateral (b) view, after embolization. Devascularization of the tumor is almost complete.



**Figure 4 a-c.** Second day post-endovascular treatment contrast-enhanced T1-weighted MRI with fat saturation: axial (a), sagittal (b) and coronal (c) plane. It well demonstrates the right nasopharyngeal mass with no-contrast enhancement zone in the center of the lesion.

### Treatment

The entire procedure is performed with the aid of the Medtronic neuronavigation.

After the positioning of medicated Codman in both nasal cavities, an attical deviation in area 3 of Cottle impacting the right middle turbinate is evident with a reduction of the surgical lumen, it is, therefore, necessary to incise the mucous membrane of the nasal septum with electro-surgical units in correspondence with the deformity; detachment of the mucopericardium and periosteum on both sides; with Fomon's scissors the osteocartilaginous deformity is incised and removed.

The mucosa of the inferior turbinate between head and body is incised with an electric scalpel and turbinotomy is performed. An uncinctomy and a broad medium meatotomy were done with exposure of the posterior wall of the maxillary sinus. We perform a plastic of the medium turbinate with body and tail removal.

Therefore, a complete view of the angiofibroma originating from the pterygopalatine fossa is obtained, obliterating the nasopharyngeal cavum and reaching the anterior wall of the sphenoid sinus preserving the limiting bone. The bone portion of the medial pterygomaxillary wall is knocked down with a diamond cutter a la demande with exposure of the pterygopalatine fossa.

The course of the pre-bifurcation sphenopalatine is identified and vascular clips are placed. The contours of the tumor are delimited with dissection and coagulation until the tumor mass is removed. Arterial bleeding of a possibly posteroinferior branch of the Sphenopalatine artery originating from an accessory bone canal inferior to Sphenopalatine is reported.

Accurate hemostasis is performed, positioning of fibrillar Tabotamp on the pterygopalatine fossa, and apposition of Floseal. A merocell is positioned in the right nasal cavity.

### Outcome and follow-up

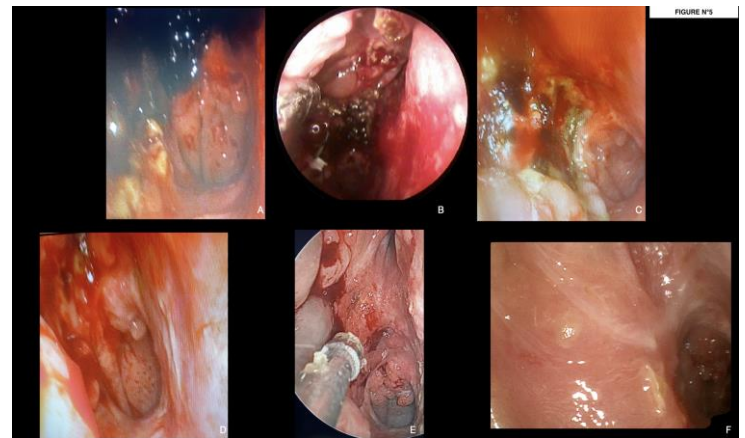
We performed a follow-up visits on the 10th, 21th, 30th, 40th, 60th day and the last control at a 12th month after the surgery.

During the follow-up visits, we gently removed crusts and suctioned secretions in nasal fiber optic angled at 0°, 30° and 45° rigid and/or flexible endoscopy. No evidence of residual mass, and good hemostasis.

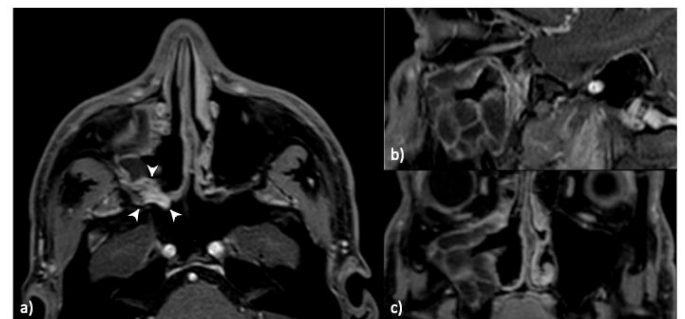
We have restored the permeability of the right nasal fossa. We have noted a polypoid mass occupying the right maxillary cavity that requires medical local therapy (Figure 5).

Two months after surgery, the control MRI demonstrated the removal of the lesion with the presence of delimited tissue hypointense in T1-weighted sequences, hyperintense in T2-weighted sequences, and prominent contrast-enhancement in post-contrast T1-weighted images (Figure 6) – in the right pterygopalatine fossa. Right maxillary sinusitis was associated.

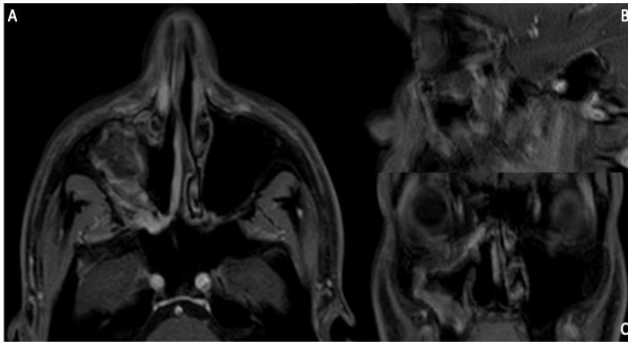
The control MRI at 12th month substantially a radiological improvement of the right maxillary sinusopathy (Figure 7).



**Figure 5 a-f.** Follow up visits. No evidence of residual mass. The permeability of the right nasal fossa was restored. A) at ten days from the surgery ; B) at twenty one days from the surgery; C) at thirty days from the surgery; D) at forty days from the surgery; E) at sixty days from the surgery; F) at 12th month from the surgery.



**Figure 6 a-c.** A two-months follow-up contrast-enhanced T1-weighted MRI with fat saturation: axial (a), sagittal (b) and coronal (c) plane. It shows a delimited tissue with prominent contrast-enhancement is in the right pterygopalatine fossa (arrowheads) and homolateral maxillary sinusitis (asterisk).



**Figure 7 a-c.** A year follow-up contrast-enhanced T1-weighted MRI with fat saturation: axial (a), sagittal (b) and coronal (c) plane. It shows a stable radiological situation with an absence of sinusopathies.

### 3. Discussion

The advance in the endoscopic surgery approach in cases of such complexity with the support of a neuronavigation system and the possibility to perform a pre-operative embolization lead to a change in the management of JNA, making radical changes in the surgery asset. [15, 16]. The JNA that interests the nasal-sinuses cavity and pterygopalatine fossa that in the past were treated via an external approach now may be considered for endoscopic sinus-surgery removal. The use of an endoscope gives us the possibility to realize a complete view of the nasal cavity before and after exeresis of the tumor and at the same time any remnants to be identified and removed; also is imprescindible to the follow-up visit. The literature strongly evidenced how in these last years the increased experience in the endoscopic endonasal approach makes feasible the resection also of large or an extended tumors.

1. Another important additional help is the new endoscopic bipolar cautery forceps and the use of intraoperative neuronavigation that help us to perform a more safe and efficacy endoscopic surgery. [4,9,17]

2. Angiography with angioTC is important to planning the vascular target to perform the embolization and future surgery. Preoperative embolization of JNA may largely reduce intraoperative blood loss, the most important problem for a good endoscopic approach, a clean operative field during endoscopic procedures gives us the possibility to perform a better dissection that leads to a lower recurrence rate. The literature described a 60% reduction in intraoperative blood loss when preoperative embolization was carried out. The principal blood supply is offered by the ipsilateral maxillary artery, but in minor quantity also the contralateral external carotid, and some JNA receive blood supply from the ipsi and contralateral internal carotid system. It's important to consider also that embolization isn't a technique exempt from risks, but these are less important concerning the advantages.[17-20]

3. The MRI study is important in the preoperative phase and during a surveillance period after the surgery time. The MRI does manifest any of the inflammatory changes that, after 3–4 months, often underline the differentiation between small residual active lesions and normal scar tissue. [4, 21]

### References

- Safadi A, Schreiber A, Fliss DM, Nicolai P. Juvenile Angiofibroma: Current Management Strategies. *J Neurol Surg B Skull Base*. 2018 Feb;79(1):21-30. doi: 10.1055/s-0037-1615810. Epub 2018 Jan 18. PMID: 29404237; PMCID: PMC5796815;
- López F, Triantafyllou A, Snyderman CH, Hunt JL, Suárez C, Lund VJ, Strojan P, Saba NF, Nixon IJ, Devaney KO, Alobid I, Bernal-Sprekelsen M, Hanna EY, Rinaldo A, Ferlito A. Nasal juvenile angiofibroma: Current perspectives with emphasis on management. *Head Neck*. 2017 May;39(5):1033-1045. doi: 10.1002/hed.24696. Epub 2017 Feb 15. PMID: 28199045.;
- Boghani Z, Husain Q, Kanumuri VV, Khan MN, Sangvhi S, Liu JK, Eloy JA. Juvenile nasopharyngeal angiofibroma: a systematic review and comparison of endoscopic, endoscopic-assisted, and open resection in 1047 cases. *Laryngoscope*. 2013 Apr;123(4):859-69. doi: 10.1002/lary.23843. Epub 2013 Mar 11. PMID: 23483486;
- Nicolai P, Villaret AB, Farina D, Nadeau S, Yakirevitch A, Berlucchi M, Galtelli C. Endoscopic surgery for juvenile angiofibroma: a critical review of indications after 46 cases. *Am J Rhinol Allergy*. 2010 Mar-Apr;24(2):e67-72. doi: 10.2500/ajra.2010.24.3443. PMID: 20338105.
- Coutinho-Camillo CM, Brentani MM, Nagai MA. Genetic alterations in juvenile nasopharyngeal angiofibromas. *Head Neck*. 2008 Mar;30(3):390-400. doi: 10.1002/hed.20775. PMID: 18228521.
- Coutinho-Camillo CM, Brentani MM, Nagai MA. Genetic alterations in juvenile nasopharyngeal angiofibromas. *Head Neck*. 2008 Mar;30(3):390-400. doi: 10.1002/hed.20775. PMID: 18228521.
- Alshaiikh NA, Eleftheriadou A. Juvenile nasopharyngeal angiofibroma staging: An overview. *Ear Nose Throat J*. 2015 Jun;94(6):E12-22. doi: 10.1177/014556131509400615. PMID: 26053985.
- Szymańska A, Szymański M, Czekajska-Chehab E, Szczerbo-Trojanowska M. Invasive growth patterns of juvenile nasopharyngeal angiofibroma: radiological imaging and clinical implications. *Acta Radiol*. 2014 Jul;55(6):725-31. doi: 10.1177/0284185113506189. Epub 2013 Oct 16. PMID: 24132768.
- Wormald PJ, Van Hasselt A. Endoscopic removal of juvenile angiofibromas. *Otolaryngol Head Neck Surg*. 2003 Dec;129(6):684-91. doi: 10.1016/s0194-5998(03)01580-8. PMID: 14663436.
- Zanation AM, Mitchell CA, Rose AS. Endoscopic skull base techniques for juvenile nasopharyngeal angiofibroma. *Otolaryngol Clin North Am*. 2012 Jun;45(3):711-30, ix. doi: 10.1016/j.otc.2012.03.008. PMID: 22588045.
- Leong SC. A systematic review of surgical outcomes for advanced juvenile nasopharyngeal angiofibroma with intracranial involvement. *Laryngoscope*. 2013 May;123(5):1125-31. doi: 10.1002/lary.23760. Epub 2013 Apr 2. PMID: 23553370.
- Rogers DJ, Bevans SE, Harsha WJ. Endoscopic resection of juvenile nasopharyngeal angiofibroma. *Adv Otorhinolaryngol*. 2012;73:132-6. doi: 10.1159/000334470. Epub 2012 Mar 29. PMID: 22472245.
- Wilson WR, Miller D, Lee KJ, Yules RB. Juvenile nasopharyngeal angiofibroma. *Laryngoscope*. 1972 Jun;82(6):985-97. doi: 10.1288/00005537-197206000-00006. PMID: 4338568
- Hicks JL, Nelson JF. Juvenile nasopharyngeal angiofibroma. *Oral Surg Oral Med Oral Pathol*. 1973 Jun;35(6):807-17. doi: 10.1016/0030-4220(73)90119-9. PMID: 4350909
- Schroth G, Haldemann AR, Mariani L, Remonda L, Raveh J. Preoperative embolization of paragangliomas and angiofibromas. Measurement of intratumoral arteriovenous shunts. *Arch Otolaryngol Head Neck Surg*. 1996 Dec;122(12):1320-5. doi: 10.1001/archotol.1996.01890240028007. PMID: 8956743.
- Galletti C, Freni F, Ciodaro F, Galletti B. Congenital bilateral choanal atresia: an endoscopic approach with multi-flaps supported by neuronavigated CT. *BMJ Case Rep*. 2021 Nov 2;14(11):e245815. doi: 10.1136/bcr-2021-245815. PMID: 34728511; PMCID: PMC8565542.
- Pryor SG, Moore EJ, Kasperbauer JL. Endoscopic versus traditional approaches for excision of juvenile nasopharyngeal angiofibroma. *Laryngoscope*. 2005 Jul;115(7):1201-7. doi: 10.1097/01.MLG.0000162655.96247.66. PMID: 15995507.

18. Antonelli AR, Cappiello J, Di Lorenzo D, Donajo CA, Nicolai P, Orlandini A. Diagnosis, staging, and treatment of juvenile nasopharyngeal angiofibroma (JNA). *Laryngoscope*. 1987 Nov;97(11):1319-25. doi: 10.1288/00005537-198711000-00014. PMID: 2823033.
19. Siniluoto TM, Luotonen JP, Tikkakoski TA, Leinonen AS, Jokinen KE. Value of pre-operative embolization in surgery for nasopharyngeal angiofibroma. *J Laryngol Otol*. 1993 Jun;107(6):514-21. doi: 10.1017/s002221510012359x. PMID: 8393907.
20. Pandolfo I, Vinci S, Salamone I, Granata F, Mazziotti S. Evaluation of the anterior ethmoidal artery by 3D dual volume rotational digital subtraction angiography and native multidetector CT with multiplanar reformations. Initial findings. *Eur Radiol*. 2007 Jun;17(6):1584-90. doi: 10.1007/s00330-006-0519-4. Epub 2006 Dec 21. PMID: 17186248.
21. Herman P, Lot G, Chapot R, Salvan D, Huy PT. Long-term follow-up of juvenile nasopharyngeal angiofibromas: analysis of recurrences. *Laryngoscope*. 1999 Jan;109(1):140-7. doi: 10.1097/00005537-199901000-00027. PMID: 9917056.