

## Case Report

# THYROID HEMIAGENESIS WITH PAPILLARY CARCINOMA: A CASE REPORT WITH LITERATURE REVIEW

Abdulwahid M. Salih,<sup>1</sup> Ari M. Abdullah,<sup>2,3</sup> Imad J. Habibullah,<sup>1</sup> Rawa M. Ali,<sup>2,4</sup> Shko H. Hassan,<sup>1</sup> Mohammed A. HamaAli,<sup>1</sup> Kanaw A. Salih,<sup>5</sup> Shewaz Tariq Latif,<sup>6</sup> Hiwa O. Abdullah,<sup>7,8</sup> Fahmi H. Kakamad<sup>7-10</sup>

<sup>1</sup>Department of Head and Neck Surgery, Smart Health Tower, Sulaymaniyah; <sup>2</sup>Department of Pathology, Smart Health Tower, Sulaymaniyah; <sup>3</sup>Department of Pathology, Sulaymaniyah Teaching Hospital, Sulaymaniyah; <sup>4</sup>Department of Pathology, Hospital for the Treatment of Chemical Weapons Victims, Halabja; <sup>5</sup>Department of Anesthesiology, Smart Health Tower, Sulaymaniyah; <sup>6</sup>Shahid Dr. Aso Hospital, Sulaymaniyah; <sup>7</sup>Department of Scientific Affairs, Smart Health Tower, Sulaymaniyah; <sup>8</sup>Kscien Organization for Scientific Research (Middle East Office), Sulaymaniyah; <sup>9</sup>Department of Clinical Sciences, College of Medicine, University of Sulaimani, Sulaymaniyah; <sup>10</sup>Department of Thoracic and Vascular Surgery, Smart Health Tower, Sulaymaniyah, Iraq

## ARTICLE INFO

### Article history:

Received 16 February 2026

Accepted 7 April 2026

Published 13 May 2026

### Keywords:

thyroid; hemiagenesis; papillary carcinoma; lobectomy.

## ABSTRACT

The coexistence of thyroid hemiagenesis (THA) and papillary thyroid carcinoma (PTC) is an exceedingly rare condition. This report presents a case of THA with PTC. A 36-year-old woman presented with a one-month history of dyspnea. On examination, the thyroid gland appeared asymmetrical. Neck ultrasound revealed a hypoechoic nodule in the right lobe, classified as Thyroid Imaging Reporting and Data System (TI-RADS) 4. The isthmus and left thyroid lobe were not visualized, suggesting THA. A right thyroid lobectomy was performed, and histopathological examination revealed PTC. Of the 7 reviewed cases of THA with PTC, left lobe agenesis was observed in 4 patients and right lobe agenesis in 3. Fine-needle aspiration cytology was performed in 3 cases, all of which confirmed malignancy. Five cases underwent thyroidectomy, and two underwent lobectomy. The recovery in all cases was satisfactory. Although the coexistence of THA and PTC is extremely rare, the possibility should not be overlooked.

© EuroMediterranean Biomedical Journal 2026

## Introduction

Thyroid hemiagenesis (THA) is a rare congenital anomaly characterized by the complete absence of one thyroid lobe due to failure of embryonic development.<sup>1</sup> It primarily affects females, with the left lobe most commonly involved. The prevalence of THA ranges from 0.02% to 0.2%. It is frequently an incidental finding during routine thyroid evaluations or check-ups. The exact mechanism underlying this congenital anomaly remains unknown, although a genetic predisposition has been suggested.<sup>2</sup>

Most patients with THA are euthyroid, with normal levels of triiodothyronine (T3) and thyroxine (T4).<sup>3</sup> Multiple associations of THA with various thyroid disorders have been documented in the literature. These include simple goiter, nodular goiter, toxic and non-toxic thyroid adenomas, Graves' disease, Graves' ophthalmopathy, Hashimoto's thyroiditis, and subacute thyroiditis. Nodular goiter appears to be the most commonly associated condition, whereas THA associated with malignant thyroid neoplasms is rare, with only a few cases reported in the literature.<sup>4</sup> This report presents a case of left thyroid lobe agenesis with papillary thyroid carcinoma (PTC) in the right lobe. The eligibility of the references was confirmed, and the case was written in accordance with the CaReL guidelines.<sup>5,6</sup>

\* Corresponding author: Fahmi H. Kakamad, [kakamad,fahmi@gmail.com](mailto:kakamad,fahmi@gmail.com)  
All rights reserved. ISSN: 2279-7165 - Available on-line at [www.embj.org](http://www.embj.org)

**Case Report**

**Patient information**

A 36-year-old woman presented with a one-month history of dyspnea. She had no significant past medical or family history, while her past surgical history included a cesarean section.

**Clinical findings**

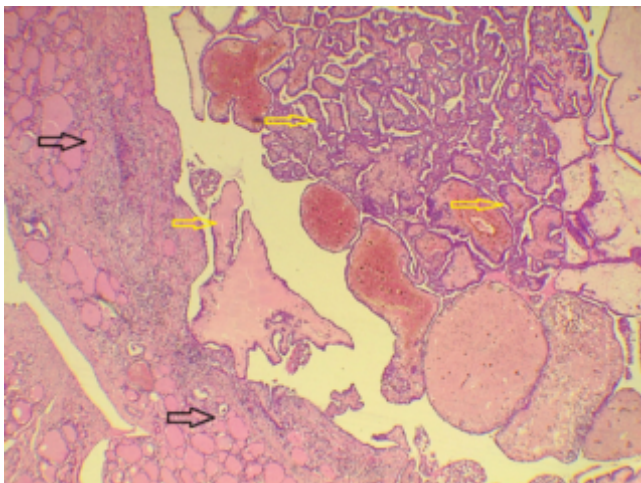
On physical examination, the thyroid gland was asymmetrically palpable; the left lobe was not appreciable, while a firm, well-defined nodule was detected in the right thyroid region. There were no overlying skin changes, tenderness, or cervical lymphadenopathy. Oral cavity examination and vital signs were within normal limits.

**Diagnostic approach**

Routine laboratory tests were within normal ranges, including thyroid-stimulating hormone (1.10 µIU/mL), free T3 (4.28 pmol/L), free T4 (13.98 pmol/L), serum calcium (8.95 mg/dL), and serum thyroglobulin (13 ng/mL). Neck ultrasound demonstrated a normal right thyroid lobe measuring 63×20×18 mm with homogeneous echotexture and normal vascularity. However, within the mid-third of the right lobe, a predominantly hypoechoic nodule measuring 17×9×6 mm was identified and classified as Thyroid Imaging Reporting and Data System (TI-RADS) 4. The isthmus and left thyroid lobe were not visualized, consistent with THA. Fine-needle aspiration cytology of the TI-RADS 4 nodule demonstrated a hypercellular smear with papillary fronds, overlapping cell clusters, and dispersed cells with oval nuclei, irregular membranes, nuclear grooves, and intranuclear pseudoinclusions. The cytoplasm was moderately eosinophilic in a hemorrhagic background containing multinucleated giant cells and macrophages. Overall, the findings were diagnostic of Bethesda category VI.

**Therapeutic intervention**

The patient underwent a right thyroid lobectomy. The right recurrent laryngeal nerve and parathyroid glands were identified and preserved during the procedure. Histopathological analysis confirmed conventional PTC (Figure 1). The tumor was unifocal, measuring 1.4 cm, and exhibited well-differentiated morphology. There was no evidence of lymphovascular or perineural invasion, and the lymphocytic infiltrate was minimal. Necrosis and extrathyroidal extension were absent, and mitotic activity was 0/2 mm<sup>2</sup>. No tumor capsule was identified. All resection margins were free of tumor, with no additional pathological abnormalities noted. Based on the American Joint Committee on Cancer (AJCC) 8th edition, the pathological stage was pT1b.



**Figure 1.** The section shows papillary tissue composed of follicles, filled with colloid material (dark arrows), and exhibiting complex papillary structures with fibrovascular cores (yellow arrows) (hematoxylin and eosin stain, 4x).

**Table 1.** Summary of reported cases of papillary thyroid carcinoma with thyroid hemigenesis.

Author, year	Age (years)	Gender	Clinical findings	PMH	TSH	Agnesis site	FNA cytology	Lymph node involvement	Management	Follow-up
Lee <i>et al.</i> , 2024 <sup>9</sup>	37	F	Anterior neck swelling	None	Normal	Left lobe	2×3×3.3 cm nodule (Bethesda VI)	No	Total thyroidectomy	Uneventful recovery; on oral levothyroxine; adjuvant radioactive iodine ablation
George <i>et al.</i> , 2022 <sup>7</sup>	30	F	Infrathyroid neck swelling	None	Normal	Right lobe and isthmus	1×1.5 cm firm nodule (classical type papillary carcinoma thyroid with thyroiditis)	No	Total thyroidectomy	Uneventful recovery
Alqahtani <i>et al.</i> , 2021 <sup>2</sup>	36	F	Neck swelling	None	Normal	Right lobe	3.5×2.5×1.5 cm parathyroid adenoma, a 2 mm PTMC involving the superior pole of the left lobe associated with lymphocytic thyroiditis and multinodular goiter	No	Left lobectomy with inferior parathyroidectomy	Uneventful recovery
Meng <i>et al.</i> , 2023 <sup>11</sup>	40	M	Neck swelling	None	Normal	Left lobe	1.2×0.7 cm nodule was suggestive of PTC	No	Total thyroidectomy	Uneventful recovery
	46	F	Unknown	None	Unknown	Left lobe	Not performed	No	GTET	No recurrence after 10 months; satisfactory cosmetic outcome; no surgical complications
Gandla <i>et al.</i> , 2020 <sup>8</sup>	20	F	Left thyroid swelling	None	Normal	Right lobe	PTC	No	Left hemithyroidectomy	Uneventful recovery
Park <i>et al.</i> , 2016 <sup>6</sup>	47	F	Incidental finding	None	Normal	Left lobe	PTC	Yes	Total thyroidectomy with bilateral central compartment node dissection	Uneventful recovery

PMH, past medical history; TSH, thyroid-stimulating hormone; FNA, fine-needle aspiration; PTMC, papillary thyroid microcarcinoma; PTC, papillary thyroid carcinoma; GTET, Gasless transaxillary endoscopic thyroidectomy.

### Follow-up and outcome

The patient was discharged on the second postoperative day following an uneventful recovery. Postoperative thyroglobulin was 0.04 ng/mL, and serum calcium was 9.29 mg/dL.

## Discussion

THA was first documented by Handfield-Jones in 1866, and its exact etiology remains unknown.<sup>1,7</sup> The condition shows a female-to-male predominance of approximately 3:1. Left-lobe agenesis is most common, followed by isthmic agenesis, while right-lobe agenesis is the least common.<sup>7</sup> The absence of one thyroid lobe usually does not cause symptoms and is often discovered incidentally during evaluation for disorders in the remaining lobe. Therefore, the true prevalence of this congenital abnormality remains difficult to ascertain.<sup>1</sup> In such cases, the underdeveloped or missing lobe is frequently smaller, while the functioning lobe may enlarge due to compensatory hyperplasia.<sup>8,9</sup> The present case was a young female with complaints of only dyspnea without any other associated symptoms and enlargement of the functioning lobe. In terms of diagnosis and imaging, ultrasonography is the primary modality for detecting thyroid abnormalities, as it effectively reveals the gland's anatomy and structural changes. Thyroid scintigraphy plays a complementary role in evaluating suspected THA, particularly in distinguishing true agenesis from ectopic thyroid tissue. While ultrasonography is the primary modality for assessing anatomical absence, it may miss ectopic tissue outside the cervical region. In contrast, scintigraphy using technetium-99m or iodine isotopes provides functional imaging and can detect metabolically active thyroid tissue regardless of location, helping to exclude ectopic tissue that may mimic hemiagenesis. The absence of uptake in the thyroid bed, with no ectopic uptake, supports true agenesis, whereas radiotracer uptake at ectopic sites indicates thyroid dysgenesis. Scintigraphy is especially useful when ultrasound findings are inconclusive; however, results should be interpreted with caution, as non-visualization may also occur in conditions such as thyroiditis or suppressed function and should be correlated with anatomical imaging.<sup>9,10</sup> Given the straightforward nature of the present case and the comprehensive results of neck ultrasonography, thyroid scintigraphy was not performed, as it would not have contributed to decision-making or the management plan.

Various pathological conditions – such as follicular adenoma, multinodular goiter, chronic thyroiditis, and Graves' disease – are frequently encountered. However, the combination of THA and PTC is exceedingly rare.<sup>1,2</sup> A literature search was conducted using Google Scholar and PubMed, focusing on English-language publications. The search strategy employed the keywords “thyroid hemiagenesis” and “papillary” to identify relevant studies. To ensure contemporary relevance, the search was restricted to articles published within the last 10 years. Given that this study is a case-based summary review rather than a systematic review, priority was given to the most recently published cases in order to reflect current diagnostic and management practices. Inclusion criteria were cases of THA associated with PTC with histopathological confirmation within the specified time frame. Hence, 7 cases were reviewed to provide only a contemporary overview (Table 1). Among them, most of the cases (6/7) were female. Left-lobe agenesis was reported in 4 cases, while right-lobe agenesis was observed in 3 cases. Neck swelling was the most frequently reported presenting symptom (5/7). Fine-needle aspiration cytology was performed in 3 cases, all of which confirmed malignancy. Lymph node involvement was documented in one case.

The American College of Radiology's TI-RADS system stratifies thyroid nodules by ultrasound features to guide management. Nodules are scored TR1-TR5: TR1 (benign) and TR2 (not suspicious) need no biopsy. TR3 (mildly suspicious) warrants biopsy if  $\geq 2.5$  cm or follow-up if  $\geq 1.5$  cm. TR4 (moderately suspicious) requires biopsy if  $\geq 1.5$  cm or follow-up if  $\geq 1$  cm. TR5 (highly suspicious) calls for biopsy if  $\geq 1$  cm or follow-up if  $\geq 0.5$  cm.<sup>3</sup> Imaging of the present case revealed a TI-RADS 4 thyroid nodule measuring 1.7 cm, indicative of a moderately suspicious lesion. Hence, a fine needle aspiration biopsy was taken from the nodule, and the results revealed Bethesda category VI cytology, thus indicating malignancy and the need for lobectomy or near-total thyroidectomy.

The treatment strategy for thyroid carcinoma in patients with THA does not differ from that applied to individuals with anatomically normal thyroid glands. However, variations in the location of the parathyroid glands and in the course of the recurrent laryngeal nerve may occur in hemiagenesis, necessitating heightened intraoperative caution by the surgeon.<sup>1</sup> As the tumor is confined to the solitary lobe, hemithyroidectomy effectively removes all thyroid tissue, equivalent to a total thyroidectomy. Reported cases of this rare coexistence

describe standard hemithyroidectomy with intraoperative confirmation of contralateral lobe agenesis and preservation of the recurrent laryngeal nerve, parathyroids, and surrounding vasculature on the absent side.<sup>8</sup> The presence of hemiagenesis should not alter fundamental surgical principles; the extent of resection should be guided primarily by the tumor's oncologic risk profile. According to the 2025 American Thyroid Association guidelines, high-risk features such as extrathyroidal extension, lymph node metastasis, or tumor size  $>4$  cm warrant more extensive resection with appropriate nodal clearance.<sup>11,12</sup>

The present case underwent a right thyroid lobectomy with the preservation of the recurrent laryngeal nerve, and histopathological examination of the resected specimen revealed a unifocal PTC of the classic variant. The patient's recovery was uneventful. Similarly, among the reviewed cases, 5 patients underwent thyroidectomy and 2 underwent lobectomy, and postoperative recovery was satisfactory in all cases. It is worth noting that the treatment in all cases was through open surgery, except one case managed with gasless transaxillary endoscopic surgery.<sup>13</sup> Asymptomatic cases of THA should undergo regular follow-up to monitor for the potential development of thyroid malignancies and other related conditions. Identifying THA before surgery is crucial to prevent unnecessary exploration of the contralateral neck, which could increase the risk of injury to surrounding structures.<sup>7</sup> For such a reason, our case underwent lobectomy, as THA was preoperatively confirmed. The limitations of this report were a lack of long-term follow-up and a limited number of cases in the literature review section.

## Conclusions

Although the coexistence of THA and PTC is exceedingly rare, this case highlights important clinical lessons. Accurate preoperative identification of THA is essential for guiding surgical planning, avoiding unnecessary exploration of the contralateral neck, and reducing the risk of complications.

**Contributions:** Abdulwahid M. Salih, Ari M. Abdullah, Rawa M. Ali, Shko H. Hassan: conceptualization; Shko H. Hassan, Ari M. Abdullah, Mohammed A. HamaAli: data curation; Abdulwahid M. Salih, Imad J. Habibullah, Kanaw A. Salih, Fahmi H. Kakamad: methodology; Shewaz Tariq Latif, Hiwa O. Abdullah: writing – original draft; Hiwa O. Abdullah, Fahmi H. Kakamad, Rawa M. Ali: writing – review & editing. All authors approved the final version of the manuscript and agreed to be accountable for all aspects of the work.

**Conflict of interest:** the authors have no conflict of interest to declare.

**Ethics approval and consent to participate:** no ethical committee approval was required for this case report because this article does not contain any studies with human participants or animals. Informed consent was obtained from the patient included in this study.

**Consent for publication:** written informed consent was obtained from the patient for the publication of any related data and accompanying images in this report.

**Availability of data and materials:** the data regarding this case can be provided by the corresponding author upon reasonable request.

## References

- Park I, Choi JH, Kim JH, Kim JS. Thyroid Hemiagenesis Associated with Papillary Thyroid Carcinoma. *Int J Thyroidol* 2016;9:43-6.
- Alqahtani SM, Alanesi S, Alalawi Y. Thyroid hemiagenesis with primary hyperparathyroidism or papillary thyroid carcinoma: A report of two cases and literature review. *Clin Case Rep* 2021;9:1615-20.
- Sereke SG, Oriekot A, Bongomin F. Thyroid hemiagenesis with a TI-RADS 2 nodule in the contralateral lobe. *Thyroid Res* 2021;14:10.
- Pizzini AM, Papi G, Corrado S, et al. Thyroid hemiagenesis and incidentally discovered papillary thyroid cancer: case report and review of the literature. *J Endocrinol Invest* 2005;28:66-71.
- Abdullah HO, Abdalla BA, Kakamad FH, et al. Predatory publishing lists: a review on the ongoing battle against fraudulent actions. *Barw Med J* 2024.
- Prasad S, Nassar M, Azzam AY, et al. CaReL guidelines: a consensus-based guideline on case reports and literature review (CaReL). *Barw Med*

- J 2024;2:13-9.
7. George A, Rajan P, Viswanath UA, et al. A Rare Case of Right Thyroid Hemiogenesis Associated with Papillary Carcinoma in Remnant Lobe. *Kerala Surgical Journal* 2022;1;28:91-2.
  8. Gandla S, Halkud R, Siddappa KT, et al. Thyroid Hemiogenesis and Papillary Carcinoma: a Rare Association. *Indian J Surg Oncol* 2020;11:84-6.
  9. Lee CH, Ong YP, Hayati F, et al. Thyroid Hemiogenesis: An Incidental Discovery during Treatment for Papillary Thyroid Carcinoma. *J Med Ultrasound* 2024;32:352-4.
  10. Jain TK, Meena RS, Bhatia A, et al. Dual thyroid ectopia-role of thyroid scintigraphy and neck ultrasonography. *Indian J Nucl Med* 2015;30:338-40.
  11. Dhingra S, Juneja R, Tigga A. Papillary Carcinoma of Thyroglossal Cyst with Thyroid Hemiogenesis: Is Conservative Surgical Management Enough? *Indian J Otolaryngol Head Neck Surg* 2022;74:1992-5.
  12. American Thyroid Association. 2025 ATA Differentiated Thyroid Cancer Guidelines: Extent of surgery. *Clinical Thyroidology® for the Public* [Internet]. American Thyroid Association 2025;18:4-5. Available from: <https://www.thyroid.org/patient-thyroid-information/ct-for-patients/december-2025/vol-18-issue-12-p-4-5/> (cited 6 Apr 2026).
  13. Meng K, Chen X, Shen W, Xin Y. Gasless transaxillary endoscopic surgery for papillary thyroid carcinoma in a patient with thyroid hemiogenesis: An appropriate choice or not? *Asian J Surg* 2023;46:4545-6.