

CLITOROPLASTY AND LABIA MAJORA HYPERTROPHY SURGICAL CORRECTION IN A MOSAICISM X0/XY: CASE REPORT

Michela Massa, Maria Stella Leone, Carlo Neumaier, Carlo Introini, Pierluigi Santi

Abstract

The goal of genital correction surgery is to create a cosmetic and functional outcome preserving the sensitivity. A case of correction for hypertrophy of the clitoris and *labia majora* is described. A 46 years old women, diagnosed at infancy with X0/XY mosaicism, presented in early childhood, hypertrophy of clitoris and *labia majora*. She underwent surgery to remove gonads in infancy, but she asked for reduction clitoroplasty and *labia majora* only after a long psicotherapic support. A small area of the clitoris to be preserved was marked. Neurovascular bundle was carefully separated from the corporal tissue that was cut off. Later the estimated amount of skin and fat to be removed from *labia majora* was marked. At 12 months after surgery, the patient's external genitalia had reached a normal appearance. The sensitivity of the surgically reduced clitoris had preserved and *labia majora* aspect had a good cosmetic result.

Keywords: clitoris, plastic surgery, labia majora

Address of the authors:

Plastic and Reconstructive Surgery Department, National Institute of Cancer Research (IST), University of Genoa, Italy.

Send correspondence:

Dr. Massa Michela
Email: michela.massa@yahoo.it

Received: February 10th, 2010

Revised: February 19th, 2010

Accepted: February 23th, 2010

Language of the Article: English.

No conflicts of interest were declared.

© CAPSULA EBURNEA, 2010
ISSN: 1970-5492

DOI: 10.3269/1970-5492.2010.5.9

Introduction

Several disorders of sexual development are known. Causes could be genetic (such as in Turner Syndrome, Klinefelter Syndrome or Mosaicism X0/XY), hormonal (such as in Congenital Adrenal Hyperplasia), drugs or tumors (1). Clitoromegaly and *labia majora* hypertrophy could be some of the features. A case of a 46-aged woman with X0/XY mosaicism with clitoris and *labia majora* hypertrophy is presented. The aim of surgery was to achieve normal clitoral morphology, preserving clitoral sensitivity to sexual stimulation and give acceptable cosmetic result.

Case Report

A 46 years old woman, diagnosed at infancy with X0/XY mosaicism by fetal lymphocytes analysis, underwent surgery in childhood to remove gonads (a testis in one side and an ovotestis in the other) and has been treated with hormonal therapy. She lives in stable heterosexual relationship with a true sexual identity but she could not have own children. She presented as adult with an enlarged clitoris and with a scrotal aspect of *labia majora*, which she found as socially embarrassing (Fig. 1). After a long psicotherapic support she referred to plastic surgery for treatment of the genital malformation. A preoperative Magnetic Resonance Imaging was performed to confirm the clinical findings. The hypertrophic clitoris was 7 centimeters long and the cavernous tissue was divided in two symmetric portions with the bulbourethral *glands* at the base of the clitoris. A clitoroplastic and the reduction of

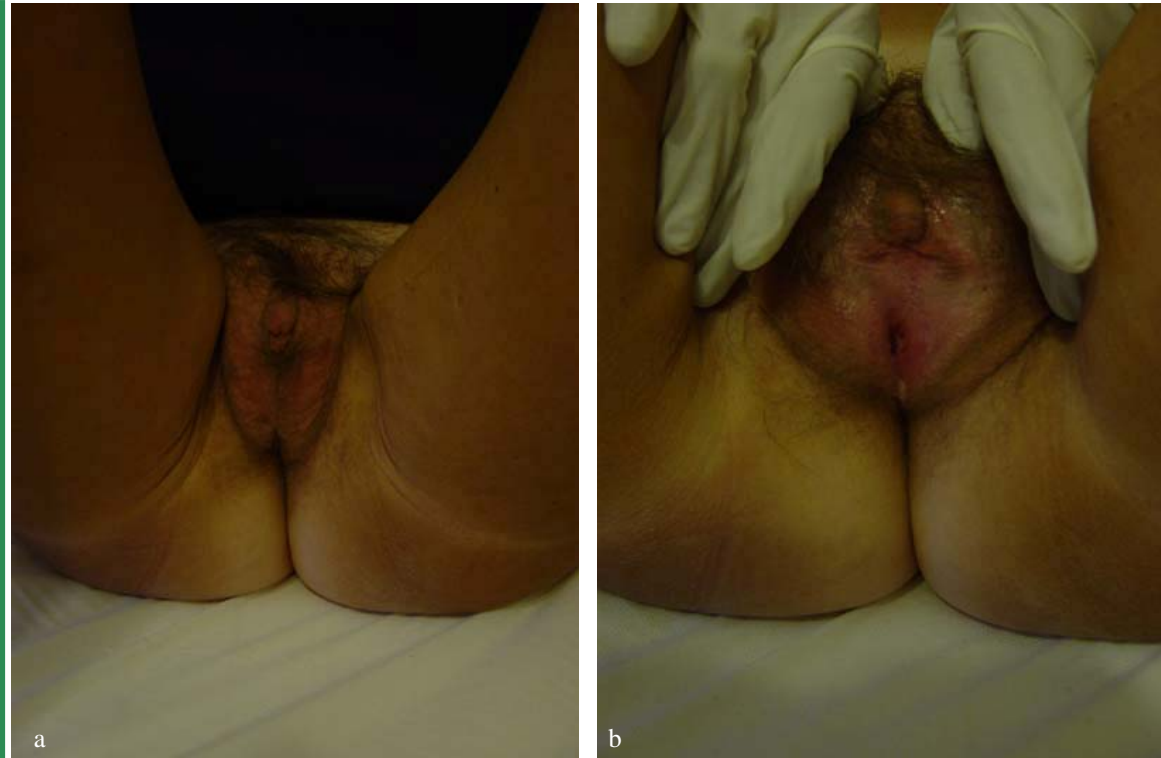

Fig. 1 a, b : Preoperative views of the enlarged clitoris and labia majora hypertrophy

labia majora were made in a one-stage procedure. A 16 Ch Foley catheter was placed into the bladder through the urethra that had a normal position. A small area of the clitoris to be preserved was designed and a longitudinal dorsal incision was made and extended proximally on the shaft of the clitoris beneath the *mons veneris* (Fig. 2). Dorsal neurovascular bundle was separated from the corporal tissue, preserving sensitivity. Cavernous tissue was then cut off and *glans clitoris* with neurovascular bundle repositioned at the appropriate site (Fig. 3 and 4). The estimated amount of skin and fat to be removed was marked. In this case, more was to be removed from the left side than from the right side. Resection of the area's skin and subcutaneous fat was performed with an "S italics" incision following preoperative markings. After meticulous haemostasis, two layers of 3/0 absorbable running sutures were placed, one in the deep fat and another in the subdermis, until the wound edges were approached. A 5/0 mononylon running suture closed the skin. These sutures provided strong support to all this very mobile area, avoiding dead spaces and bleeding because postoperative compressive bandages are difficult to hold in this region (Fig. 5).

Postoperative result was satisfactory. At 12

months after surgery, the patient's external genitalia had reached a normal appearance (Fig. 6). The preserved portion of the clitoris was still present and no discomfort

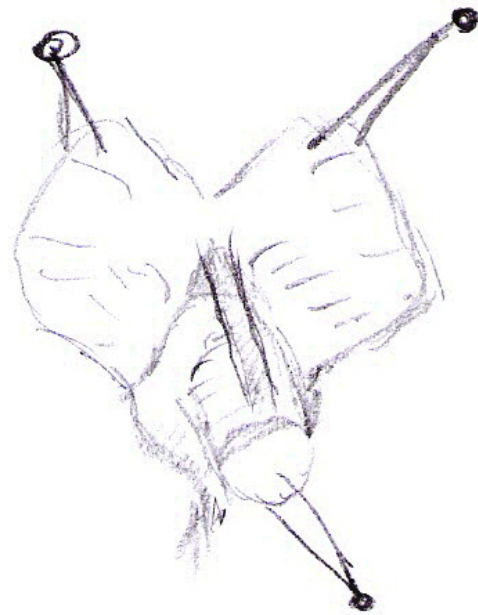


Fig. 2: Enlarged clitoris is dissected off the corpora cavernosa and retracted posteriorly to reach the crural bifurcation. The dorsal neurovascular bundle is preserved.

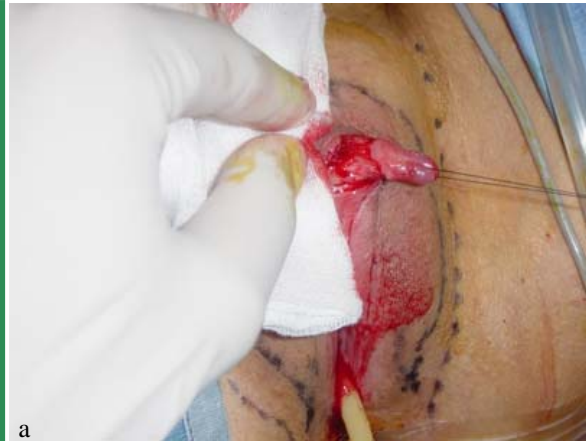

Fig. 3 a, b : The clitoris with the neurovascular bundle is separated from the ventral corporal tissue, that are completely excised.

had been seen with the pubic lesion. Sensation and sexual satisfaction were reported to be normal and satisfactory at short follow-up. She did not report dryness or other problems during coitus. The patient is very pleased with the final cosmetic result.

Conclusion

The aim of feminizing genitoplasty is to recreate the normal female anatomy. In the past the enlarged clitoris structure was amputated. This procedure could achieve a satisfactory cosmetic result and was supported by the theory that the clitoris had no function (2). But previous papers have emphasized the importance of the clitoris in psychosexual development (3).

Patients who had clitorrectomy were shown to have sexual inhibition and ambivalence towards sexual activity (4). Subsequently Lattimer (5) described a more refined technique, recession clitoroplasty, in which the clitoris is reduced and relocated preserving the sensitive top of the glans. The need to maintain the anatomical position of the clitoris was argued later by Randolph and Hung (6). But the disadvantage was evident during sexual activity, when the recessed corporeal bodies fixed to pubic bone become enlarged and painful. Novel techniques of reduction were suggested in the 1970s (7,8). In particular it was suggested to leave untouched ventral mucosa along a third of circumference to preserve blood supply to the glans (9). The actual approach of many authors is to preserve as much of the dorsal neurovas-



b

cular bundle (10) as possible. Some authors claim that reducing size of clitoris, except in extreme cases of clitoral virilization and lifting the dorsal nerve off the tunica are not necessary and cause a possible damage resulting in a compromised sexual responsiveness (11). In contrast leaving too much erectile tissue may cause pain during sexual activity, when it has been fixed to pubic bone. So reducing the size of the erectile body, preserving the majority of erectile tissue and the nerves could be a good compromise (12). Gradually surgeons started including labioplasty to the technique of clitoroplasty using the dorsal excess foreskin to reconstruct the rudimentary or absent *labia minora* (13). Although several authors refer *labia minora* problems, *labia majora* hypertrophy is not reported frequently. The technique of removing the excess tissue has been reported by Felicio (14), and more recently by Mottura (15). The removal *labia majora* excess in its lateral part has been reported to give the vaginal area a natural appearance and normal sensitivity.

The one stage procedure, even if not in early age, would be an attractive way of correcting the anatomic abnormalities of these patients, giving a good functional and aesthetic result after surgery. Although these patients have several dis-

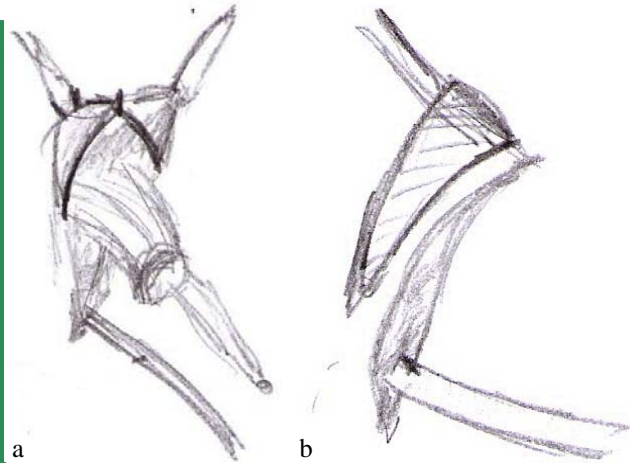


Fig. 4 a, b: Excessive preputial skin is removed.

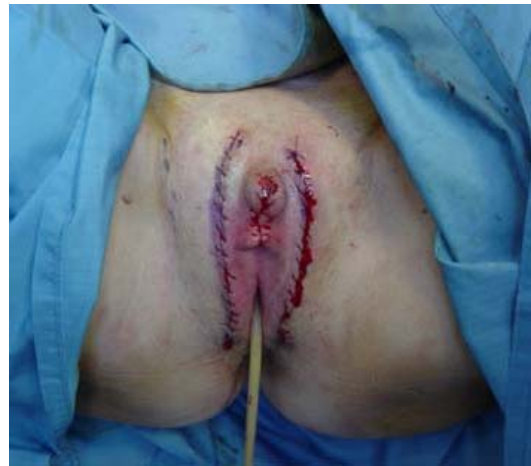

Fig. 5: Intraoperative view after suture of the flaps.

couraging problems to face, such as finding a sexual identity, the impossibility of having children and psychological stress for operations and hormonal therapy (1), the clitoroplasty method followed by *labia majora* hypertrophy correction should guarantee normal external appearance preserving the sensitive function.

This operative technique that take care to avoid damage to dorsal neurovascular bundle is a good perspective for all women that desire to maintain a satisfactory sexual life not renouncing to a normal female aspect.



Fig. 6: Twelve months later, postoperative view is satisfactory.

Rererences

1. Frost-Arner L, Aberg M, Jacobsson S: Clitoral sensitivity after surgical correction in women with adrenogenital syndrome: a long term follow-up. *Scand J Plast Reconstr Surg Hand Surg* 2003;37:356-359.
2. Jones HW Jr, Jones GES: The gynaecological aspects of adrenal hyperplasia and allied disorders. *Am J Obstet Gynecol* 1954;68:1330-1365.
3. Master WH, Johnson VE: Human sexual response. Boston: Little, Brown & Co 1966.
4. Mininberg DT: Phalloplasty in congenital adrenal hyperplasia. *J Urol* 1981;128:355-356.
5. Lattimer JK: Relocation and recession of the enlarged clitoris with preservation of the glans: an alternative to amputation. *J Urol* 1961;86:113-116.
6. Randolph JG, Hung W: Reduction clitoroplasty in females with hypertrophied clitoris. *J Pediatr Surg* 1970; 5:224-231.
7. Kumar H, Kiefer JH, Rosenthal IE, Clark SS: Clitoroplasty: experience during a 19-year period. *J Urol* 1974;111:81-84.
8. Lean WL, Hutson JM, Deshpande AV, Grover S: Clitoroplasty: past, present and future. *Pediatr Surg Int.* 2007;23:289-293.
9. Fonkalsrud EW, Kaplan S, Lippe B: Experience with reduction clitoroplasty for clitoral hypertrophy. *Ann Surg* 1977;186:221-226.
10. Sagehashi N: Clitoroplasty for clitoromegaly due to adrenogenital syndrome without loss of sensitivity. *Plast Reconstr Surg.* 1993;91:950-955.
11. Baskin LS: Anatomical studies of the female genitalia: surgical reconstructive implications. *J Pediatr Endocrinol Metab.* 2004;17:581-587.
12. Baskin LS, Erol A, Li YW, Liu WH, Kurzrock E, Cunha GR: Anatomical studies of the human clitoris. *J Urol.* 1999;162:1015-1022.
13. Kogan SJ, Smey P, Levitt SB: Subtunical total reduction clitoroplasty: a safe modification of existing techniques. *J Urol* 1983;130:746-748.
14. Felicio Y: Labial surgery. *Aesth Surg J* 2007;27:322-328.
15. Mottura AA. Labia Majora Hypertrophy. *Aesthetic Plast Surg.* 2009; in press.

CLITOROPLASTICA E RICOSTRUZIONE CHIRURGICA DELLE GRANDI LABBRA IN MOSAICISMO X0/XY: CASE REPORT

Lo scopo della correzione chirurgica delle malformazioni genitali dovute a disordini del differenziamento sessuale è di ottenere un buon risultato estetico ma anche funzionale, preservando la sensibilità. Una donna di 46 anni, diagnosticata in infanzia come affetta da un mosaicismo X0/XY, presentava una ipertrofia del clitoride e delle grandi labbra. Fu sottoposta in età infantile a un intervento chirurgico finalizzato a rimuovere le gonadi, ma solo dopo un lungo percorso di psicoterapia, richiese un intervento di riduzione delle grandi labbra e del clitoride. L'area del clitoride da preservare fu marcata. Il fascio neurovascolare fu separato attentamente dai corpi cavernosi, che furono asportati. Successivamente venne asportato l'eccesso di cute e grasso dalle grandi labbra. A 12 mesi dall'intervento, i genitali hanno assunto un aspetto normale. La sensibilità del clitoride è stata preservata e le grandi labbra hanno assunto un buon risultato estetico.

Parole chiave: clitoride, chirurgia plastica, grandi labbra.

CAPSULA EBURNEA, 5(9):50-54, 2010
